

## Original Research Article

## Outcome of Early Retrograde Closed Intramedullary Fixation of Fracture Shaft of Femur by Titanium Elastic Nail in Children

Mohammad Ashfaqur Rahman<sup>1\*</sup>, Sarwar Ibney Salam<sup>2</sup>, Quazi Shahidul Alam<sup>3</sup>, Nazrana Islam Jui<sup>4</sup>, Faysal Ahmmed<sup>5</sup>, Iftheer Irfan<sup>6</sup>

<sup>1</sup>Consultant, Department of Paediatric Orthopaedic Surgery, Health and Hope Hospital, Dhaka, Bangladesh

<sup>2</sup>Professor, Department of Paediatric Orthopaedic Surgery, National Institute of Traumatology & Orthopaedic Rehabilitation (NITOR), Dhaka, Bangladesh

<sup>3</sup>Assistant Professor, Department of Paediatric Orthopaedic Surgery, Dhaka Medical College Hospital, Dhaka, Bangladesh

<sup>4</sup>Medical officer, Bangladesh Public Service Commission (BPS), Dhaka, Bangladesh

<sup>5</sup>Registrar, Department of Orthopedic Surgery, Bangladesh Medical College Hospital, Dhaka, Bangladesh

<sup>6</sup>Assistant Surgeon, National Institute of Traumatology & Orthopaedic Rehabilitation (NITOR), Dhaka, Bangladesh

### Article History

Received: 02.03.2024

Accepted: 08.04.2024

Published: 27.04.2024

### Journal homepage:

<https://www.easpublisher.com>

### Quick Response Code



**Abstract: Background:** Paediatric femoral shaft fractures are common in orthopaedic practice and can be managed using various modalities, each with its advantages and disadvantages. The Titanium Elastic Nailing System has emerged as a promising treatment option, offering potential advantages over traditional methods. **Objective:** This study aimed to evaluate the functional and radiological outcomes and operative complications of paediatric femoral shaft fractures treated with the Titanium Elastic Nailing System. **Methods:** A prospective interventional study was conducted from July 2020 to July 2021. Thirty children aged 6-14 years (mean age 11.32 ±3.76) were selected using purposive sampling and strict inclusion/exclusion criteria. Patients were followed up for at least 24 weeks at four-week intervals, and outcomes were assessed using Flynn's TEN scoring criteria. **Results:** All 30 patients completed the study. Radiological union was achieved in 80.0% of cases within 7-10 weeks, with 90.0% of patients able to bear full weight by the 12th week. Minor complications occurred in 20.0% of cases, while no major complications were reported. 80.0% of cases had excellent outcomes, 20.0% were satisfactory, and no poor outcomes were observed. **Conclusion:** The Titanium Elastic Nailing System is an excellent method for treating paediatric femoral shaft fractures, demonstrating high rates of radiological union and functional recovery with a low incidence of complications.

**Keywords:** Femoral shaft fractures, Children, Titanium Elastic Nail, Early fixation, outcome.

**Copyright © 2024 The Author(s):** This is an open-access article distributed under the terms of the Creative Commons Attribution **4.0 International License (CC BY-NC 4.0)** which permits unrestricted use, distribution, and reproduction in any medium for non-commercial use provided the original author and source are credited.

## INTRODUCTION

Femoral shaft fractures are common injuries in the paediatric population, representing roughly 1.6% of all bony injuries in children [1]. They are among the most common major paediatric injuries treated by orthopaedic surgeons [2]. The appropriate management of femoral shaft fractures in children is a subject of much debate. Fractures in children younger than six years of age can often be managed conservatively, while adolescents may benefit from antegrade locked intramedullary nail fixation [3].

Treatment options range from strictly nonsurgical methods such as closed reduction with spica casting or traction followed by casting, to surgical stabilization using intramedullary devices, external

fixators, or internal fixation with plates and screws [4]. Titanium elastic nailing, also known as elastic stable intramedullary nailing, has become the preferred choice of stabilization in pediatric long bone fractures. It aims to stabilize the fracture, control length and alignment, promote bone healing, and minimize morbidity. The Titanium Elastic Nailing System (TENS) is ideal for pediatric femur fractures due to its ease of use, functioning as an internal splint providing six-point fixation.

In diaphyseal femur fractures in children aged 5 to 15 years, recovery is often incomplete with conservative treatment, and issues like angulation, shortening, and malrotation may not be fully corrected. Noncompliance or intolerance to plaster for prolonged

\*Corresponding Author: Mohammad Ashfaqur Rahman

Consultant, Department of Paediatric Orthopaedic Surgery, Health and Hope Hospital, Dhaka, Bangladesh

periods and psychological problems must be considered. Fixation of pediatric femur fractures ideally produces an "internal splint" that shares loads, maintains reduction until hard callus formation, and does not endanger the femoral head's growth arrest or blood supply [5].

A minimally invasive procedure is associated with reduced soft tissue trauma, more rapid recovery, shorter hospital stays, earlier mobilization or early functional activity, encouraging faster healing, preserving muscle tone, restoring joint movements, promoting mental recovery, and preventing psychosocial complications [6]. Flexible intramedullary nail fixation meets these requirements by allowing rapid mobilization, potentially no risk of osteonecrosis, low risk of physical injury, and reduced risk of refracture. Titanium Elastic Nailing (TENs), also known as elastic stable intramedullary nailing (ESIN), has become the preferred stabilization method in pediatric femoral shaft fractures [7].

## OBJECTIVES

### General Objectives

- To evaluate the outcome of treatment of fractured shaft of femur in children using titanium elastic nailing.

### Specific objectives

- To evaluate the functional outcome after surgery.
- To assess the radiological outcome.
- To find operative complications

## MATERIALS AND METHODS

### Study Design

This prospective observational study was conducted from July 2020 to July 2021 at the Department of Orthopaedics, Dhaka Medical College Hospital (DMCH), Dhaka. The study included all patients aged 5-15 years with clinical and radiological evidence of a closed fracture shaft of the femur. The study aimed to evaluate the functional and radiological outcomes and the operative complications of paediatric femoral shaft fractures treated with the Titanium Elastic Nailing System.

### Inclusion criteria

- Patients are between 5 to 15 years of age.
- Diaphyseal fracture of femur: displaced, undisplaced, and rotational malalignment.
- Closed fracture.
- Fractures within 14 days of trauma.

### Exclusion criteria

- Open fracture
- Patient with associated fracture in other parts of the femur.
- Covid 19 positive patient

- Pathological Fracture
- Soft tissue infection.
- Suspected bony infection.
- Body weight > 50 kg
- Fractures with neurovascular deficit.
- Fractures required open reduction.
- Segmental fracture shaft of the femur.

### Data Collection

Data were collected prospectively from July 2020 to July 2021 at the Department of Orthopaedics, Dhaka Medical College Hospital. The study included all patients aged 5-15 years with clinical and radiological evidence of closed femoral shaft fractures. Data compilation involved meticulous editing, thorough checking, and rechecking to correct any omissions or inconsistencies. All patient information was recorded systematically in preformed data collection sheets, and quantitative data were expressed as mean and standard deviation. In contrast, qualitative data were expressed as frequency distribution and percentage.

### Data Analysis

The data were systematically recorded in preformed data collection sheets, with quantitative data presented as mean and standard deviation and qualitative data as frequency distribution and percentage. Standard statistical analysis was conducted using SPSS version 26.0 to analyze various variables. A significance level of 0.05 was set for all analyses, with a p-value <0.05 considered significant. This approach ensured a comprehensive and rigorous data analysis, allowing for meaningful interpretations and conclusions to be drawn from the study findings.

### Surgical Procedure

The surgical procedure begins with the patient under spinal anesthesia in a supine position. The affected leg is exposed and draped in a sterile manner. Entry points are marked on the lateral aspects of the distal femur and proximal tibia, followed by small incisions at these points. Guide wires are inserted through these incisions, across the fracture site, and into the intramedullary canal under fluoroscopic guidance. The canal is prepared using a cannulated reamer, and pre-bent titanium elastic nails are inserted over the guide wires. The nails are positioned to span the fracture site and engage the proximal and distal fragments. The distal tip of the nail is locked using a suitable mechanism, and the incisions are closed in layers. Postoperatively, the patient is monitored closely for complications and provided with appropriate pain management and rehabilitation protocols. Regular follow-up visits are scheduled to assess fracture healing and functional outcomes.

### Ethical consideration

Before the study, the research protocol received approval from the Research Review Committee and the Ethical Review Committee of the Department of Orthopaedics, Dhaka Medical College (*Ref: Memo No.*

*ERC-DMC/ECC/2020/111*). The study's aims and objectives were explained to patients and their legal guardians in a local language and informed written consent was obtained from the legal guardians. Participants were informed about the approximate cost of implants and instrumentation. It was ensured that all informed consents and records remained confidential and would only be used for research purposes. No financial

support was received from any organization or individual, and no financial benefits were provided to participants for the study. These ethical considerations were essential to maintain the integrity and validity of the research.

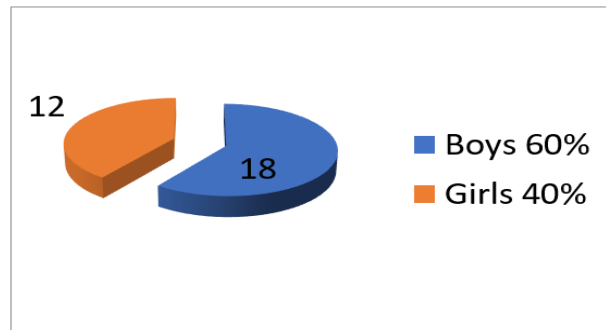
## RESULTS

**Table 1: Distribution of patients by age**

Age group	Number of patients	Percentage
6-8	7	23.33
9-11	15	50.00
12-14	8	26.67

The patients in this study ranged in age from 6 to 14 years. Maximum patients 15(50%) were 9-11 years, 8(26.67%) were in 12-14 years, 7(23.33%) were in 6-8

years. The mean age was  $11.32 \pm 3.76$  years results are shown in Table -1.



**Figure 1: Showing Distribution of patients by gender**

In this study, most patients were boys 18(60.00%) and girls 12(40.00%). Boys were predominant in this study. The results are shown in Figure 1.

**Table 2: Mechanism of injury**

Injury mechanism	Number of patients	Percentage
Road traffic accident	17	56.67
Fall from height	10	33.33
Sports Injury	3	10.00

In this series, most of the patients sustained trauma by road traffic accidents 17(56.67%) and 10 (33.33%) fell from height, results shown in Table 2.

**Table 3: Distribution by Time interval between injury and surgery with union time**

Variable	Number of patients	Percentage
<b>Time Interval</b>		
>1	25	83.33
≤ 1 week	5	16.67
<b>Duration of union</b>		
7-10 Weeks	24	80.00
11-14 Weeks	6	20.00
<b>Weight-bearing</b>		
12 <sup>th</sup> week	27	90.00
14 <sup>th</sup> week	3	10.00

Among 30 patients, a maximum of 25(83.33%) were operated within 8 to 14 days of injury, and 5(16.67%) were within seven days. The mean interval

between injury and surgery was  $10.42 \pm 2.42$  days. Results are shown in Table 3. Radiological evaluation of fracture site union showed that 24(80%) cases united

within 7-10 weeks and 6(20%) cases united within 10-14 weeks. The mean union time was 9.75+1.62 SD weeks. Out of 30 cases, after assessing the radiological status of

the union, full weight bearing was possible in 27 (90.0%) patients in the 12th week and the rest 3(10.0%) in the 14th week.

**Table 4: Distribution of patients by status of minor complications**

Variable	Number of patients	Percentage
<b>Duration</b>		
Absent	24	80.00
Minor	6	20.00
<b>Complications</b>		
Knee motion restriction	3	10.00
Skin irritation	4	13.33
Bursa formation	2	6.66

At the end of 24<sup>th</sup> week follow-up, out of 30 patients, 24 (80.0%) had no complications, and 6

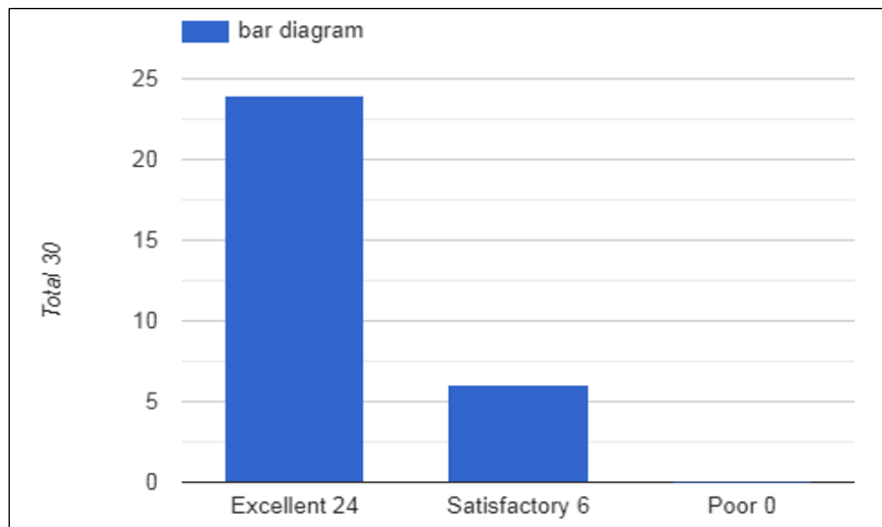
(20.0%) had minor and no major complications. Results are shown in Table 4.

**Table 5: Outcome of patients based on TEN scoring criteria**

Result	Number of patients	Percentage
Excellent	24	80
Satisfactory	6	20
Poor	0	0

Evaluation of the final Outcome revealed that satisfactory results in excellent 24(80.0%) and

satisfactory results were found in 6(20.0%) cases and no poor results. Results are shown in Table 5.



**Figure 2: Evaluation of Outcome revealed that satisfactory results**

## DISCUSSION

In this study, 30 cases were selected based on specific inclusion and exclusion criteria, mirroring the approach in [8]. The age range of patients was 6 to 14 years, with the majority (50%) falling between 9 and 11 years, 26.67% in the 12-14 years range, and 23.33% in the 6-8 years range. The mean age was 11.32 ± 3.76 years, similar to the findings of [9]. Who reported a mean age of 10.8 years in a range of 6 to 14 years. Among the 30 patients, there were 18 (60.0%) males and 12 (40.0%) females, with a male-to-female ratio of 3:2. This ratio was comparable to the study by Lokesh *et al.*, where the male-to-female ratio was 2:1.

The most common cause of fractures was road traffic accidents (56.67%), followed by falls from height (33.33%), with the remaining cases attributed to sports-related injuries. The Distribution of fracture types was consistent with previous studies, with transverse fractures being the most common (60.0%), followed by oblique (16.67%) and spiral (23.33%) fractures. This pattern aligns closely with studies by [10], which reported similar distributions of fracture types. Most fractures occurred in the middle third of the shaft (76.67%), followed by the proximal third (16.67%) and the distal third (6.67%), consistent with findings by [11].

Regarding the timing of surgery, the majority of patients (83.33%) underwent surgery more than a week after the injury, with a mean interval of  $10.42 \pm 2.42$  days. This delay was primarily due to the COVID-19 pandemic, which necessitated RT-PCR testing for all patients before surgery [12]. Most cases did not encounter difficulties during reduction, but closed osteoclasis was required in some cases. Other complications included difficulty passing the medial nail into the proximal fragment, which was managed by introducing the nail with the hip in slight abduction. There were also cases of blood loss, managed by packed cell transfusion, and cases where the nail penetrated the opposite cortex, which was corrected during surgery without impacting the final outcome.

Radiological evaluation showed that most cases (80.0%) achieved union within 7-10 weeks, consistent with findings by [13]. Partial weight-bearing was advised at 4 weeks for most patients (63.3%), with the rest advised at 8 weeks. Full weight-bearing was possible for the majority (90.0%) within 8-12 weeks, with the remainder taking up to 16 weeks due to the fracture pattern. Limb length discrepancy was minimal in most cases (90.0%), with only a few cases (10.0%) exhibiting shortening of less than 2 cm.

Malalignment was observed in some cases (10.0%) but was generally mild and did not require intervention. At the end of follow-up, no cases reported pain at the affected site, and most patients (86.67%) exhibited a wide range of knee motion. Complications were minor, with skin irritation at the nail insertion site and bursa formation being the most common [14]. Overall, the final outcomes were excellent in 80.0% of cases and satisfactory in 20.0%, comparable to previous studies.

This study provides valuable insights into the epidemiology, management, and outcomes of femoral shaft fractures in children, demonstrating outcomes consistent with previous literature [15]. The findings highlight the importance of careful preoperative planning, meticulous surgical technique, and close postoperative monitoring to achieve optimal outcomes in pediatric femoral shaft fractures.

## CONCLUSION

The Titanium Elastic Nailing System (TENS) is the preferred method for pediatric femoral shaft fractures due to its minimally invasive nature, providing six-point fixation and yielding excellent functional and cosmetic results. TENS enables early ambulation, shorter hospital stays, and higher parent satisfaction compared to other treatment methods. Its efficacy is supported by studies showing excellent outcomes in a majority of cases, making it a reliable choice for managing femoral shaft fractures in pediatric patients.

## Recommendation

- Frequent follow-up should be recommended.
- A longer follow-up period should be recommended.
- A comparative study can be recommended.
- Cases can be collected from two or more centers.

## Acknowledgments

I extend my heartfelt gratitude to Prof. Dr. Md. Shah Alam, Prof. Dr. Fakrul Amin Khan, and my teachers at DMCH for their invaluable guidance and support—special thanks to Dr. Sarwar Ibne Salam for his continuous assistance. I also thank my colleagues, patients, and hospital staff for cooperating. My most profound appreciation goes to my family, especially my wife, and the children and parents who participated in this study.

**Study Purpose:** To evaluate the efficacy of the Titanium Elastic Nailing System (TENS) for pediatric femoral shaft fractures.

**Key Findings:** TENS provides six-point fixation, allowing early ambulation and shorter hospital stays. It offers excellent functional and cosmetic results with higher parent satisfaction compared to other treatments.

**Newer Findings Added to What is Known:** TENS shows promising outcomes for femoral shaft fractures in children, emphasizing its minimally invasive nature and favorable functional outcomes.

## Abbreviations

AP: Anterior – Posterior  
ATLS: Advanced Trauma Life Support  
ESIN: Elastic Stable Intramedullary Nail  
LLD: Limb length discrepancy  
TENS: Titanium Elastic Nailing System  
TEN: Titanium Elastic Nail

**Funding:** No funding sources.

**Conflict of Interest:** None declared.

## REFERENCES

1. Gardner, M. J., Lawrence, B. D., & Griffith, M. H. (2004). Surgical treatment of pediatric femoral shaft fractures. *Current opinion in pediatrics*, 16(1), 51-57.
2. Galano, G. J., Vitale, M. A., Kessler, M. W., Hyman, J. E., & Vitale, M. G. (2005). The most frequent traumatic orthopaedic injuries from a national pediatric inpatient population. *Journal of Pediatric Orthopaedics*, 25(1), 39-44.
3. Lascombes, P., Haumont, T., & Journeau, P. (2006). Use and abuse of flexible intramedullary nailing in children and adolescents. *Journal of Pediatric Orthopaedics*, 26(6), 827-834.



4. Khazzam, M., Tassone, C., Liu, X. C., Lyon, R., Freeto, B., Schwab, J., & Thometz, J. (2009). Use of flexible intramedullary nail fixation in treating femur fractures in children. *Am J Orthop*, 38(3), E49-E55.
5. Gupta, P., Sahu, R. L., & Huria, A. (2014). Acute uterine inversion: a simple modification of hydrostatic method of treatment. *Annals of medical and health sciences research*, 4(2), 264-267.
6. Rajak, M. K., Thakur, R., Choudhary, A., Bhaduri, I., & Kumar, S. (2016). Titanium elastic nailing in femoral diaphyseal fractures in children of 6-14 years age. *Acta Orthop Belg*, 82(4), 883-888.
7. Anastasopoulos, J., Petratos, D., Konstantoulakis, C., Plakogiannis, C., & Matsinos, G. (2010). Flexible intramedullary nailing in paediatric femoral shaft fractures. *Injury*, 41(6), 578-582.
8. Mishra, A. K., Chalise, P. K., Shah, S. B., Adhikari, V., & Singh, R. P. (2013). Diaphyseal femoral fractures in children treated with titanium elastic nail system. *Nepal Med Coll J*, 15(2), 95-7.
9. Ahmad, M., Rahman, F. N., Islam, M. M., & Majumder, M. R. U. (2014). Death due to poisoning- a medicolegal study at dhaka medical college, dhaka. *Faridpur Med Coll J*, 9(2), 76-79.
10. Galpin, R. D., Willis, R. B., & Sabano, N. (1994). Intramedullary nailing of pediatric femoral fractures. *Journal of Pediatric Orthopaedics*, 14(2), 184-189.
11. Moroz, L. A., Launay, F., Kocher, M. S., Newton, P. O., Frick, S. L., Sponseller, P. D., & Flynn, J. M. (2006). Titanium elastic nailing of fractures of the femur in children: predictors of complications and poor outcome. *The Journal of Bone & Joint Surgery British Volume*, 88(10), 1361-1366.
12. Busch, M. T., Perkins, C. A., Nickel, B. T., Blizzard, D. J., & Willimon, S. C. (2019). A quartet of elastic stable intramedullary nails for more challenging pediatric femur fractures. *Journal of Pediatric Orthopaedics*, 39(1), e12-e17.
13. Tamrakar, R., Basnyat, S., Shah, G. M., Bhatta, T. R., Gyawali, B., Acharya, B. M., ... & Pradhan, N. M. S. (2017). Flexible intramedullary nailing for femoral diaphyseal fractures in children. *Journal of College of Medical Sciences-Nepal*, 13(4), 420-424.
14. Mehlman, C. T., Nemeth, N. M., & Glos, D. L. (2006). Antegrade versus retrograde titanium elastic nail fixation of pediatric distal-third femoral-shaft fractures: a mechanical study. *Journal of orthopaedic trauma*, 20(9), 608-612.
15. Gupta, Y., Jha, R. K., Ghimire, N., Mishra, B. N., & Karn, N. K. (2016). Retrograde titanium elastic nailing in management of length unstable pediatric femoral shaft fracture. *Indian J Orthop*, 2, 407-414.

---

**Citation:** Mohammad Ashfaqur Rahman, Sarwar Ibney Salam, Quazi Shahidul Alam, Nazrana Islam Jui, Faysal Ahmmed, Ifthear Irfan (2024). Outcome of Early Retrograde Closed Intramedullary Fixation of Fracture Shaft of Femur by Titanium Elastic Nail in Children. *EAS J Orthop Physiother*, 6(2): 21-26.

---