

## Original Research Article

## “Study of the Outcome of Treatment of Fracture Neck Femur by Austin Moore Prosthesis with Autogenous Cancellous Bone Graft”

Md. Matiur Rahman<sup>1\*</sup>, Shamrukh Khan<sup>2</sup>, Abu Hassanat Mostafa Zamal<sup>3</sup><sup>1</sup>Assistant Professor (Orthopaedic Surgery), Sheikh Hasina Medical College, Jamalpur, Bangladesh<sup>2</sup>Junior Consultant (Neuromedicine), United Hospital Dhaka, Bangladesh<sup>3</sup>Assistant Professor (Orthopedic), Sheikh Hasina Medical College, Jamalpur, Bangladesh**Article History****Received:** 13.05.2021**Accepted:** 18.06.2021**Published:** 26.06.2021**Journal homepage:**<https://www.easpublisher.com>**Quick Response Code**

**Abstract: Background:** During nineteenth century, the advice of Sir Astley Cooper (1892) with regard to high femoral neck fractures was to treat the patients and let the fracture go. He recognized that most patients who sustained this injury tolerated prolong immobilization very poorly. Any treatment which requires prolong immobilization will care for the hazards like cardio-pulmonary problems, thrombo-embolic phenomena, urinary tract problems and decubitus ulcer in the elderly patients. **Objective:** To evaluate the effectiveness of replacement hemiarthroplasty by Austin-Moore prosthesis with autogenous cancellous bone graft in treatment of fracture neck of femur. **Materials and Methods:** This is a prospective observational study carried out at Dhaka Medical College, Orthopaedic Surgery Department from June 2006 to December 2007. Data were collected in preformed data collection sheet which included history, physical examination, radiographic findings, preoperative monitoring, and post-operative follow-up. Functional outcome was assessed by Harris hip scoring system. Total score of ten clinical parameters- pain, limp, need of support for walking, walking distance, stair climbing, put on shoes, sitting in chairs, deformity, range of motion & use of public transport finally evaluated to measure functional outcome. Evaluation of outcome assessed by Harris Hip score (HHS). Then statistical analysis was done to see comparative evaluation outcome at week 6 and at month 12 by computer based program SPSS, version 11.5. **Results:** A total of 21 cases of fracture neck femur were treated by replacement hemiarthroplasty with Austin Moore prosthesis. Autogenous cancellousbone graft harvested from resected femoral head of affected side was applied to fenestrations in the Austin Moore prosthesis in each case. Four of the twenty one patients were lost to follow-up. Of the remaining 17 patients functional outcome is evaluated. Age distribution was ranging from 65 to 85. Mean age (71.88 ±354) Sex distribution was 39% female and 41% was male. Causes of injury were 94.1% due to trivial trauma and 5.0% due to RTA. All cases sustained closed type of injury. Fracture side, 64.7% on left and 35.3% on right side. On radiographic finding in all cases fracture type were Garden type 3 and 4. Out of 17 patients, 64.7% patients had diabetes mellitus and 58.8% had hypertension. Preoperative surface traction was given along the affected limb in each case. Over three-quarter (76%) patients operation were conducted within 3 weeks of injury, while the rest (24%) were operated from 3-4 weeks after the incident of injury. Operative procedure was performed under spinal anaesthesia through posterior approach and autogenous cancellous bone graft given in the fenestration of prosthetic implant. Three (17.6%) patients developed superficial infection postoperatively. The maximum post-operative hospital stay was 21 days and minimum 14 days, the average is 17.5 days. All patients, implants were found intact in position up to 6 months of evaluation. At month 12, 1(5.9%) patient exhibited distal migration of the prosthetic stem into the medullary cavity. In this study satisfactory (excellent and good) results were observed in 47.1% cases at 6 weeks and significantly improved to 70.6% at 12 weeks, and which was maintained up to 12 months after follow up. **Conclusion:** The treatment of fracture neck of the femur which will assure early rehabilitation with unrestricted weight bearing over a stable hip joint in the elderly patients would be the treatment of choice. Most important point of consideration is the achievement of painless stable hip with large range of movements sufficient to accomplish the most important functional needs such as walking activity, prayer and other activities. From this study it was observed that

replacement hemiarthroplasty of proximal femoral component by Austin Moore prosthesis with autogenous cancellous bone graft is acceptable procedure for displaced subcapital and transcervical fractures of the femoral neck, in house hold nursing elderly patients.

**Keywords:** Fracture Neck Femur, Austin Moore Prosthesis, Autogenous Cancellous Bone Graft.

**Copyright © 2021 The Author(s):** This is an open-access article distributed under the terms of the Creative Commons Attribution **4.0 International License (CC BY-NC 4.0)** which permits unrestricted use, distribution, and reproduction in any medium for non-commercial use provided the original author and source are credited.

## I. INTRODUCTION

Ambroise Pare, the famous French surgeon, recognized the existence of fractures of the Femoral neck over 400 year ago. Sir Astley Cooper, however, appears to have been attempted to delineate clearly between fractures of femoral neck, or intracapsular fractures, and other fractures and dislocations about the hip. He believed that non-union of intracapsular fractures was related to loss of blood supply to the proximal fragment, the most femoral fractures would eventually but with a fibrous union and that such patients would suffer "permanent illness", and also said that treat the patient not the fracture when it occurs in a very elderly patient. Surgeons frustrated with problem of management of femoral neck fractures subsequently turned to primary prosthetic replacement [1]. During nineteenth century, the advice of Sir Astley Cooper (1892) with regard to high femoral neck fractures was to treat the patients and let the fracture go. He recognized that most patients who sustained this injury tolerated prolong immobilization very poorly. Any treatment which requires prolong immobilization will care for the hazards like cardio-pulmonary problems, thrombo-embolie phenomena, urinary tract problems and decubitus ulcer in the elderly patients. Therefore, the aim of all treatment was to provide immediate and unrestricted mobilization to reduce the morbidity and mortality [2]. Two mechanisms of injury had been suggested for femoral neck fractures Kocher noted that a direct blow to the lateral aspect of the trochanter or a torsional injury with a lateral rotation of the extremity may initiate the fracture. Torsional injury may initiate tension on the anterior aspect of the femoral neck and compression on the posterior aspect of the neck. Stress fractures may also occur from repetitive loading over a period of time. Forces within physiologic limits or minor falls may produce stress in osteoporotic bones [3]. Garden's classification, which is the most widely accepted classification of femoral neck fracture, is graded according to the degree of displacement. The grades correlate with the prognosis for healing and the rates of vascular necrosis or non-union. Other alternative classification system were proposed by Pauwels in which the femoral neck fracture type is based on the angle of the fracture line with the horizontal plane and AO classification system. Pauwels has attributed a higher incidence of non-union to greater shearing force in the more vertical fractures [3]. The development of avascular necrosis correlates with the extent of initial trauma and the displacement of fracture, with some question concerning the tamponading effect

of the intracapsular haematoma. In the meta-analysis by Lu-Yao *et al.* [4], the cumulative rate of avascular necrosis for displaced fractures was 11% to 19% within a 95% confidence interval. Fracture neck of the femur is one of the most common fractures in elderly people. Fractures of the neck of femur have always presented great challenges to orthopedic surgeons and remain in many ways today the unsolved fracture as far as treatment and results are concerned. With life expectancy increasing with each decade, number of geriatric patients is increasing significantly in our society and many of them are suffering from femoral neck fractures and their sequel [5]. Femoral neck fractures are entirely intracapsular and common to all intracapsular fractures; the synovial fluid bathing the fracture may interfere with the healing process. Because the femoral neck essentially has no periosteal layer, all healing must be endosteal. Angiogenic-inhibiting factors in synovial fluid also can inhibit fracture repair. All these factors, along with the precarious blood supply to the femoral head, make the healing unpredictable and non-union fairly frequent. Lu-Yao *et al.* found a cumulative rate of non-union in 23% to 37% of fractures [4]. Some individual reports, however, claim a non-union rate as low as 4%, with many around 15% [5]. Many different modalities of treatment have been developed for femoral neck fractures. The treatment depends primarily on the age of the patient and the degree of displacement of the fracture. Non-displaced or minimally displaced femoral neck fractures are treated with reduction and internal fixation. Displaced femoral neck fractures are treated according to the age of the patient, duration of the fracture and demands of the patient. Austin-Moore prosthesis is widely used in our country for the treatment of fracture neck of femur. There are several drawbacks of this prosthesis. In the osteoporotic bone of elderly patient loosening of the stem during introduction is a common problem. To overcome the problem often bone cement, allogeneic bone graft or autogenous bone graft is used. We feel that Austin Moore Replacement should be reserved for patients more than 65 years of age and those who are less active or debilitated because of other factors, because of increased acetabular wear with time in the younger individual. Credentials of hemiarthroplasty as a treatment modality for displaced transcervical fractures in the elderly have been under cloud since the advent of newer types and designs of bipolar and total hip arthroplasties. It has been a common fact that the more "active" patients often complain of pain early in their postoperative period. We

have studied the results of the Moore type of hemiarthroplasty in fresh and old transcervical fractures of the femur operated at our institute over the past one year and a half. We have evaluated our results with respect to pain, range of motion, and status of ambulation, all of which contribute to success or failure of hemiarthroplasty. We have also reviewed recent literature comparing results of cemented and uncemented hemiarthroplasties bipolar hemiarthroplasties and total hip arthroplasty. We have also studied the results with respect to age, and correlation of osteolysis and other radiological changes with pain. This study tried to evaluate the effectiveness of replacement hemiarthroplasty with the use of femoral head as autogenous cancellous bone graft to press-fit the stem of Austin-Moore prosthesis.

## II. OBJECTIVES

### General objective

- To evaluate the effectiveness of replacement hemiarthroplasty by Austin-Moore prosthesis with autogenous cancellous bone graft in treatment of fracture neck of femur.

### Specific objectives

- To assess the limb length discrepancy.
- To see the duration of hospital stay.
- To find out rate of complications.
- Final evaluation of the outcome.

## III. MATERIALS AND METHODS

Study design: Quasi Experimental Study (Clinical trial).

Place of study: Department of Orthopaedic Surgery, Dhaka Medical College and hospital, Dhaka, Bangladesh.

Period of study: June 2006 to December, 2007.

Study Population: All patients admitted in the Orthopaedic surgery department of Dhaka Medical College

Hospital, Dhaka, Bangladesh during the study period with clinical features suggestive of fracture neck femur, subsequently proved by radiological.

Sample size: Due to time limitation and financial constraint only 21 cases were selected during study period but out of them 17 cases were feasible to be included in the study, remaining 4 cases were lost to follow up.

Sampling Technique: Purposive sampling (Non-randomized) method was followed as per inclusion and exclusion criteria. 21 consecutive patients of fracture neck femur had been taken who underwent surgery during the study period. In these 21 cases, Austin Moore hemiarthroplasty had been performed at

Dhaka Medical College Hospital, Orthopaedics surgery department during the past 19 months.

### Inclusion criteria

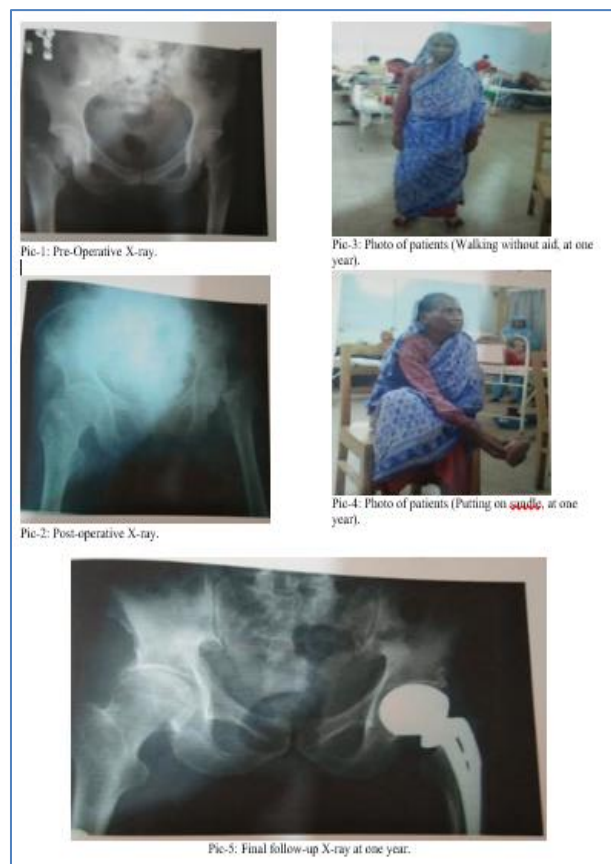1. Age: Patients having fracture neck femur at or above 65 years of age.
2. Sex: Both sexes.
3. Duration of fracture: Fractures more than 12 hours old.
4. Preservation of calcar femoralae on radiographic findings.

### Exclusion criteria

1. Osteoarthritis of the hip with unhealthy acetabulum.
2. Pathological fracture neck femur due to secondary metastasis involving head of femur.
3. Fracture neck femur associated with life threatening medical Condition.

## DATA ANALYSIS

After data processing data were analyzed with the help of computer using computer based software SPSS (version 11.5). Data were analyzed and findings were presented in tables and figures as required. Statistical analyses were done by using McNemar Chi-square ( $X^2$ ) Probability Test.



**Fig-1: Some pic pre and post-operative X-ray follow up.**

#### IV. OBSERVATIONS & RESULTS

The findings of the study derived from data analysis are presented below. Demographic characteristics: Table I shows the demographic characteristics of the patients. Of the 17 patients, 47.1% were between 65-70 years of age, 29.4% between 70-75

years, 11.8% between 75 - 80 years and another 11.8% above 80 years of age. The mean age of the patients was 71.88 ±5.54 years and the lowest and highest ages were 65 and 85 years respectively. About 59 % of the patients were male. About 59% were housewives, 23.5% retired persons and 17.6% were other occupants.

**Table-1: Distribution of patients by demographic variables (n =17)**

Variables	Frequency	Percentage
Age (Years)		
65-70	08	47.1
70-75	05	29.4
75-80	02	11.8
>80	02	11.8
Sex		
Male	07	41.2
Female	10	58.8
Occupation		
Retired person	04	23.5
Housewife	10	58.8
Others	03	17.6

\*Mean age = (71.88±5.54) years; range = (65-85) years.

Injury history: Injury history reveals that majorities (94.1%) of the injuries were caused by minor trauma and only 5.9% by road traffic accident (RTA).

Regarding type of injuries, all (100%) of the patients had closed type of injury (Table II).

**Table-II: Distribution of patients by injury history (n = 17)**

Variables	Frequency	Percentage
Causes of injury		
Minor trauma	16	94.1
RTA	01	5.9

Fracture history: Fracture history shows nearly 65% of the patients had left sided fracture and remaining 35.3% had right sided fracture. More than

three-quarter (76.5%) of the fracture were Garden type - IV and the rest Garden type -III (Table III).

**Table-III: Distribution of patients by fracture history (n = 17)**

Frequency history	Frequency	Percentage
Fracture side		
Right	06	35.3
Left	11	64.7
Fracture type		
Garden type -III	04	23.5
Garden type -V	13	76.5

Clinical characteristics at presentation: Approximately 95% patients complained of moderate pain in hip region and 5.9% severe pain. Majority

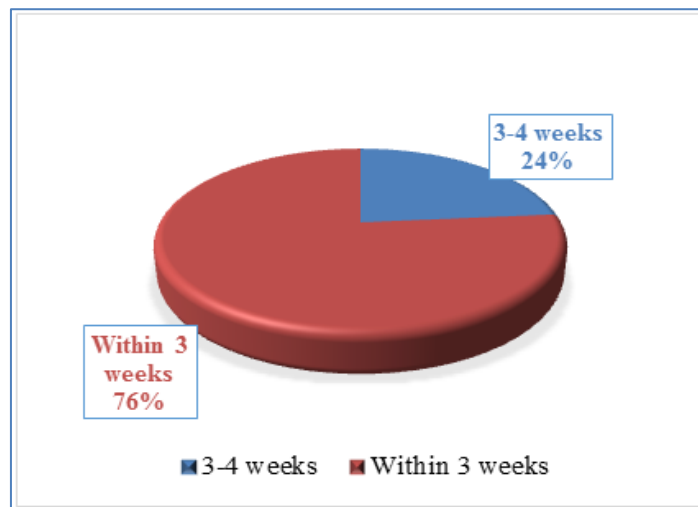
(82.4%) of the patients had 2cm or below 2cm shortening and all of the patients had mild external rotation (Table IV).

**Table-IV: Distribution of patients by clinical characteristics at Presentation (n=17).**

Variables	Frequency	Percentage
Pain in hip region		
Moderate	16	94.1
Severe	01	5.9
Shortening		
≤ 2 cm	14	82.4
> 2 cm	03	17.6
External rotation		
Mild	17	100.0

Interval between injury and operation: Figure 2 shows the interval between injury and operation. Over three-quarter (76%) patients operation of was conducted

within 3 weeks of injury, while the rest 24% were operated from 3 - 4 weeks after the incident of injury.



**Fig-2: Distribution of patients by interval between injury and operation**

Co-morbidities: Table V demonstrates the distribution of patients by co-morbidities. Or the 17

patients, 64.7% had diabetes and 58.8% were hypertensive.

**Table-V: Distribution of patients by co morbidities (n = 17).**

Co morbidities	Frequency	Percentage
DM	11	64.7
Hypertension	10	58.8

Post-operative findings: Table VI depicts the distribution of patients by postoperative findings. Majority (82.496) stayed at hospital for 2 weeks and

17.6% for 3 weeks. Three (17.6%) patients encountered superficial infection following operation.

**Table-VI: Distribution of patients by postoperative findings (n = 17).**

Variables	Frequency	Percentage
Post-operative hospital stay		
2 weeks	14	82.4
3 weeks	03	17.6
Post-operative complications		
Superficial infection	03	17.6

Postoperative evaluation: Table VII demonstrates the postoperative evaluation after 6 weeks, 12 weeks, 6 months and 12 months. No infection was found after 6 weeks. All patients' implant

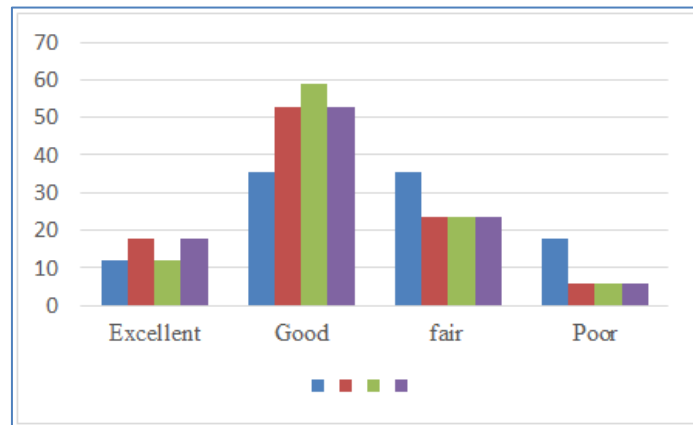was found intact in position up to 6 months of evaluation At month 12, 1(5.9%) patient exhibited displacement of implant on X-ray (distally migrated into the medullary cavity).

**Table-VII: Distribution of patients by postoperative evaluation (n = 17).**

Evaluation	After 6 weeks (n=17)	After 12 weeks (n=17)	After 6 months (n=17)	After 12 months (n=17)
Infection Prosthetic implant	00	00	00	00
Intact in position	17 (100.0)	17 (100.0)	17 (100.0)	16 (94.1)
Distal migration	00	00	00	1 (5.9)
Shortening (<3.2cm)	17 (100.0)	17 (100.0)	17 (100.0)	17 (100.0)

Outcome evaluation by Harris Hip score (HHS): Evaluation of outcome by Harris Hip Score shows that outcome at 12 weeks was better (excellent 17.6% and good 52.9%) compared to that at 6 week (excellent 11.8% and good 35.3%). At 12 week

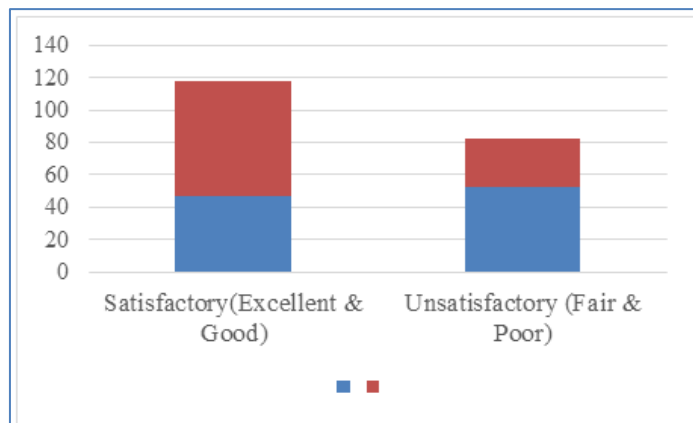excellent outcome was 17.6% and good 52.9%, while at 6 month excellent was 11.8% and good 58.8%. The outcome at 12 week and that at 12 months did not differ (Fig.3).



**Fig-3: Outcome evaluation by Harris Hip score (HHS)**

Comparative evaluation outcome at 6 week and at 12 month: Clinical evaluation of the patients at 6 weeks and at 12 months of treatment shows that 47.1% of patients had satisfactory outcome (excellent and good) which improved to 70.6% at the end of 12

months. However, the difference in improvement between 6 weeks and 12 months did not turn to significant probably due small sample size (p = 0.219) (Fig. 4).



**Fig-4: Comparative evaluation outcome at 6 week and at 12 month (n = 17).**

#Data were analysed using McNemar Chi-square ( $X^2$ ) p = 0.219

**V. DISCUSSION**

It is now well recognized that whatever the treatment to be adopted for fracture neck of the femur in the elderly patients it should allow immediate and

unrestricted rehabilitation. There is still controversy on whether treatment should be by internal fixation in the hope of achieving union without avascular necrosis or by replacement arthroplasty. Despite the modern advances in orthopaedic surgery especially in the field of femoral neck fractures, fixation by compression screws or sliding nail and plate even under control of

image intensifier, the displaced intracapsular femoral neck fractures may not end up with sound union. In many cases avascular necrosis may occur even after fracture has united. Johnston *et al*. [6], reviewing nine papers on internal fixation of femoral neck fractures, found an average failure (non-union plus avascular necrosis of the femoral head) rate of 36% (range 16 to 51%) in 2647 fractures- this compared against nine papers that favoured hemiarthroplasty as the treatment of choice in displaced fractures of the femoral neck, with an average failure rate of 13% (range 4 to 19%) in 1247 fractures. But in each series older and less fit patients were chosen for arthroplasty, and it follows that in such circumstances the results of arthroplasty are likely to be better [6]. Good results have been reported by many authors favoring replacement arthroplasty as the treatment of choice for displaced high femoral neck fractures in elderly patients. The failure rate of endoprosthetic replacement hemiarthroplasty for femoral neck fractures in the elderly have been shown ranging from 4 to 19% e.g. Hinchey and Day *et al*. [7], 16% with 1 - 8 years follow up; Jhonson and Crother *et al*. [6], 18% with 3.5 years follow up; Dekel and Weissman *et al*. [8], 4% with 1 - 11 years follow up, and Sikorski and Barrington *et al*. [9], 19% with 2 years follow up. Over past few years a broader consensus has been reached as regards treatment of fracture femoral neck in active, independent, elderly patients, they benefit from a primary arthroplasty. Austin Moore is most commonly performed procedure in developing countries. This is especially indicated in patients with relatively shorter life expectancy. Although Austin Moore prosthesis eliminates the chances of non-union and avascular necrosis, other complication still occur. The complications include deep vein thrombosis, chest infection, renal failure and bed sores. The more specific complications associated with hemiarthroplasty are infection, dislocation of implant, peri prosthetic fractures, protrusion, thigh pain and neurovascular injury [10-13]. Besides the controversies pertaining to internal fixation or prosthetic replacement for femoral neck fractures in the elderly, the patients in our country report and seek for management of their fractured femoral neck very lately, sometimes as late as one year after the injury. The problem of the late presentation is again a matter of significant consideration. Any treatment that will not assure reasonably good range of movements of the hip for functional performances such as routine prayer and squatting are not likely to be well accepted. The question arises. During the study period from June 2006 to December 2007, 21 patients aged above 65 years with displaced high femoral neck fractures treated by replacement hemiarthroplasty (Austin Moore) with autogenous cancellous bone graft. Out of these 21 patients, 4 cases were lost from subsequent 12 months follow up period, were excluded from this study. Therefore, this study comprised 17 patients of displaced subcapital or transcervical fractures of femoral neck for analysis of results of prosthetic replacement of the femoral head in the

elderly. The follow-up period was 12 months. Because of the short term follow up, evaluation of the results of such operation was difficult. Keeping this odd in mind it was observed that this study is important because (1) the incidence of this fractures in the aged peoples are very high and (2) the ideal treatment for rehabilitation of elderly patients with femoral neck fractures are yet to be shed in the context of our hospital facilities and the problems pertaining to our majority of the patients who come from indigent population of the country, In this series 47.1% were between 65 - 70 years of age, 29.4% between 70 - 75 years, 11.8% between 75 - 80 years, and another 11.8% above 80 years of age. The mean age of the patients was about 71.88 years. The age limit is arbitrary and can be justifiably reduced when the younger patients is in poor health or has a low activity level. The average age of patients in this series is lower as compared to those reported in western literature, 79 years [14]. This can be explained on the basis of lower life expectancy amongst the Bangladeshi population as compared with the West. A striking difference was found in sex incidence that is 59% were female and 41% were male. Women outnumbered men significantly in this series in keeping with the fact that femoral fractures are more common in female due to osteoporosis. Therefore, there can be no dispute about the importance of this fracture in the elderly not only as a clinical problem but also as a burden in terms of cost and total patient care. Out of 17 patients, 16 (94%) gave the history of minor trauma such as fall over a slippery ground or bath-room, or domestic stumbling and fall in a staircase or on the floor while turning out of the bed. Only one patient gave the history of less violent road traffic accident such as fall from Rickshaw. Radiological fracture type out of 17 patients 13 cases (76.5%) had Garden 4 cases (23.59) had Garden type-II which was comparable with Nather *et al*. [15], series, 83% Garden type-IV and 17% Garden type-III were chosen for Austin Moore hemiarthroplasty. All cases came into the hospital for management after two weeks of injury i.e. after the critical period of consideration of internal fixation was over. In this study 64.7% patients were diabetic and 58.8% were hypertensive. In terms of post-operative Hospital stay, majority 82.4% stayed at hospital for 2 weeks and 17.6% for 3 weeks. Patients with pre-existing illness as well as those with post operative complications tended to require a longer stay. This is comparable to other study carried out at National University Hospital, Singapore between January 1990 and 1992 treated with Moore's hemiarthroplasty. The mean hospital stay was 20 days [15]. Three (17.6%) patients encountered superficial infection. As all patients were operated through posterior approach, which is proximity to the perineum and 64.7% patients had long history of diabetes mellitus, although they were controlled before operative procedure, these may be the cause of high rate of infections. Wahab, KHA *et al*. [16], in their series reported dislocation 3.8% and 3.4%. It is worthy to mention that in this series out of 17 patients no case of a

location of the prosthesis occurred. Factors like accurate intenance of ante version of 15 to 20 degree and courte choice of head size and intenance of appropriate length of the calcar, effective closure of the posterior capsule, and most important factor Le maintenance of stable position of the hip in extension. Abduction and lateral rotation in the early pest operative days were responsible for prevention of dislocation. In this regard, this series showed superior result to any other series. In this series only one (5.99) patient developed distal migration of the prosthetic stem at one year follow up and other patients implant position were intact. In Mistry, SN [10], series have shown distal migration of the prosthesis was 10%. In this study it was probably due to chemical osteolysis or low grade deep infection. In 15% cases significant shortening was noted to a maximum of 7cm in the series of Jhadav *et al*. [17]. In this study all cases have shortening 3.2cm. In this study in every case autogenous cancellous bone graft was incorporated in the fenestrations of the Austin Moore prosthetic stem, which was harvested from resected femoral head of the affected side. It is thought that this bone graft causes early anchorage of the prosthetic implant by formation of bone through fenestrations of the prosthetic stem, which lessens distal migration as well as shortening. In this study outcome were analyzed by Harris hip score (HHS) after replacement hemiarthroplasty of femoral component by Austin Moore prosthesis with autogenous cancellous bone graft of the 10 components of HHS, support, walking distance, stair, sitting ability and able to use public transport improved significantly between week 6 to month 12. Evaluation of outcome by Harris Hip Score had shown that outcome at 12 week was better (excellent 17.6% and good 52.9%) compared to that a 6week (excellent 11.8% and good 35.3%). At 12 week excellent outcome was 17.6% and good 52.9%, while at 6 month excellent was 11.8% and good 58.8%. The outcome at 12 week and that at 12 months did not differ.... Clinical evaluation of the patients at 6 weeks and at 12 months of treatment had shown that 47.1% of patients had satisfactory outcome (excellent and good) which improved to 70.6% at the end of 12 months. This result was achieved after 12 weeks which was maintained up to 12 months, it could due to early anchorage of the prosthesis in majority of the cases. However, the difference in improvement between 6 weeks and 12 months did not turn to significant probably due small sample size ( $p = 0.219$ ). The great importance laid on the operation was rehabilitation of the elderly patients with mobility and independency as soon as possible. On the whole, the frail and aged patient, the sooner he or she was encouraged to get out of the bed and start weight bearing with gradually increasing walking. Richard Mayo *et al*. [18], said that the patients with femoral neck fractures treated by prosthetic replacement through posterior approach require little or no post operative immobilization or any external support. When the limb is held in external rotation hip remains stables and soft tissue healing is

also sound. It was agreed to the opinion of these authors and allowed these patients get out of bed within 24 to 48 hours after operation or as soon as pain permitted ambulation. Every patient then encouraged walking with unrestricted weight bearing, and in this way patients confidence restored so that they made a rapid progress from the use of walking frame with assistance to independent walking with a crutch or a cane in the opposite hand. A pressure of 20 pounds on a cane on the opposite hand can reduce static force on the operated hip by 8 to 10 times that amount [19]. In order to find out a solution to the "Unsolved fracture it is found that no reason to disagree with the outcome made by Hinchey and Day *et al*. [7], D' Acry and Devas *et al*. [2], and Jhonson *et al*. [6], advised that replacement hemiarthroplasty of the hip in elderly does not carry any excessive risk of morbidity and mortality. It is felt that given good technical expertise during the procedure, good supportive care (e.g. prophylactic antibiotics), adequate physical therapy and adequate nursing care, hemiarthroplasty by Austin Moore prosthesis with autogenous cancellous bone graft is rational choice in the treatment of displaced femoral neck fractures. It will mobilize the patient faster, decrease the morbidity rate and thus maximally improve the overall result.

## VI. CONCLUSION

The treatment of fracture neck of the femur which will assure early rehabilitation with unrestricted weight bearing over a stable hip joint in the elderly patients would the treatment of choice. Most important point of consideration is the achievement of painless stable hip with large range of movements sufficient to accomplish the most important functional needs such as walking activity, prayer and other activities. From this study it was observed that replacement hemiarthroplasty of proximal femoral component by Austin Moore prosthesis with autogenous cancellous bone graft is acceptable procedure for displaced subcapital and transcervical fractures of the femoral neck, in house hold nursing elderly patients. Associated systemic medical complications are the main factors for morbidity and mortality than due to fracture itself. However large sample size and longer follow-up will be the perfect result producing best keys. Infact, modern technology has touched many spheres of our lives. We have entered into the greater era of scientific developments. Prosthetic replacement is such a kind of inevitable advancement in orthopaedic surgery where we have already entered successfully and promising to go ahead.

## REFERENCE

1. AT, M. (1952). Metal hip joint; new self-locking vitallium prosthesis. Southern medical journal, 45(11), 1015-1019.
2. D'Arcy, J. O. H. N., & Devas, M. I. C. H. A. E. L. (1976). Treatment of fractures of the femoral neck by replacement with the Thompson prosthesis. The Journal of bone and joint surgery. British



- volume, 58(3), 279-286.
3. Budin, T. M. T. M. S. (2018). Radiation exposure to surgeon during selected orthopaedic procedures under fluoroscopic guidance technique.
  4. Lu-Yao, G. L., Keller, R. B., Littenberg, B., & Wennberg, J. E. (2005). Outcomes after displaced fractures of the femoral neck. A meta-analysis of one hundred and six published reports. *Orthopedic Trauma Directions*, 3(03), 29-33.
  5. ST, C. (2003). *Campbell's operative orthopaedics*, 10th Eds. St Louis: Mosby Inc, 1363-73.
  6. Johnston, C. E., Ripley, L. P., Bray, C. B., Shaffer, L. W., Strong, T. E., Henning, G. D., & Pruner, R. A. (1982). Primary endoprosthesis replacement for acute femoral neck fractures. A review of 150 cases. *Clinical orthopaedics and related research*, (167), 123-130.
  7. HINCHEY, J. J., & DAY, P. L. (1964). Primary prosthetic replacement in fresh femoral-neck fractures: a review of 294 consecutive cases. *JBJS*, 46(2), 223-334.
  8. Dekel, S., & Weissman, S. L. (1976, January). Immediate prosthetic replacement in fractures of femoral-neck. In *journal of bone and joint surgery-british volume* (vol. 58, no. 3, pp. 380-380). 22 buckingham street, london, england wc2n 6et: british editorial soc bone joint surgery.
  9. Sikorski, J. M., & Barrington, R. (1981). Internal fixation versus hemiarthroplasty for the displaced subcapital fracture of the femur. A prospective randomised study. *The Journal of bone and joint surgery. British volume*, 63(3), 357-361.
  10. Mistry, S.N. (1989). Analysis of the result of replacement hemiarthroplasty in Femoral neck fracture in the elderly. MS thesis, Dhaka University, Bangladesh.
  11. Dekel, S., & Weissman, S. L. (1976, January). Immediate prosthetic replacement in fractures of femoral-neck. In *journal of bone and joint surgery-british volume* (Vol. 58, No. 3, pp. 380-380). 22 buckingham street, london, england wc2n 6et: british editorial soc bone joint surgery.
  12. Raine, G. E. T. (1973). A comparison of internal fixation and prosthetic replacement for recent displaced subcapital fractures of the neck of the femur. *Injury*, 5(1), 25-30.
  13. Rydell, N. (1973). Biomechanics of hip joint, *Clin. Orthop.* 92, 6-15.
  14. Hunter, G.A. (1969). 'A comparison of the use of internal fixation and prosthetic replacement for fresh fractures of the neck of the femur', *J. Bone joint surg*, 56, 229-232.
  15. Nather, A., Seow, C. S., Iau, P., & Chan, A. (1995). Morbidity and mortality for elderly patients with fractured neck of femur treated by hemiarthroplasty. *Injury*, 26(3), 187-190.
  16. Netter, Frank, H. (2001). 'Atlas of human anatomy', 2nd ed. Icon learning system, New Jersey, 454.
  17. Jadhav, A. P., Kulkarni, S. S., Vaidya, S. V., Divekar, M. M., & Suralkar, S. P. (1996). Results of Austin Moore replacement. *Journal of postgraduate medicine*, 42(2), 33.
  18. Budin, T. M. T. M. S. (2018). Radiation exposure to surgeon during selected orthopaedic procedures under fluoroscopic guidance technique.
  19. Blount, W.P. (1956). 'Don't through away the cane', Presidential address. *American Academy of orthopaedics surgeons, J. Bone Joint surg*, 38A, 695-708.

**Citation:** Matiur Rahman *et al* (2021). "Study of the Outcome of Treatment of Fracture Neck Femur by Austin Moore Prosthesis with Autogenous Cancellous Bone Graft". *EAS J Orthop Physiother*, 3(3): 22-30.