

## Original Research Article

## Sentinel Lymph Node Biopsy Pathology and its Surgical Implications in Early-Stage Breast Cancer

Dr. Khushabu R Kabra<sup>1</sup>, Dr. Farheen Kauser<sup>2\*</sup>, Dr. Raja Sheker N<sup>3</sup><sup>1</sup>Assistant Professor in Department of Pathology in Dr Patnam Mahender Reddy Institute of Medical sciences, Hyderabad, Telangana, India- 501503<sup>2</sup>Assistant Professor in Department of Pathology in Dr Patnam Mahender Reddy Institute of Medical sciences, Hyderabad, Telangana, India- 501503<sup>3</sup>Associate Professor, Department of General Surgery, Vydehi Institute of Medical sciences, Bangalore, India- 560066**Article History**

Received: 16.03.2022

Accepted: 29.04.2022

Published: 28.05.2022

**Journal homepage:**<https://www.easpublisher.com>**Quick Response Code**

**Abstract: Background:** Sentinel lymph node biopsy (SLNB) has emerged as the standard axillary staging procedure in early-stage breast cancer, replacing routine axillary lymph node dissection (ALND) in clinically node-negative patients. This prospective observational study evaluated the pathological findings of SLNB and its surgical implications in a tertiary-care oncology setting in South India. **Methods:** Eighty female patients with histologically confirmed early-stage breast cancer (T1–T2, cN0) were enrolled between March 2021 and January 2022. SLNB was performed using a dual-technique approach with technetium-99m radiocolloid and patent blue dye. Intraoperative frozen section analysis and postoperative paraffin-embedded histopathology with immunohistochemistry were performed. Patients with positive SLNs underwent completion ALND. Outcomes including morbidity, lymphoedema rates, and patient satisfaction were compared between SLNB-alone and SLNB+ALND groups. **Results:** The sentinel node identification rate was 95% (76/80). Of these, 31.6% (24/76) had SLN metastasis, with macrometastasis in 58.3% and micrometastasis in 41.7% of positive cases. Tumour size, histological grade, and lymphovascular invasion showed statistically significant associations with SLN positivity ( $p < 0.05$ ). The SLNB-alone group demonstrated significantly lower rates of lymphoedema (2.6% vs 28.6%), seroma (5.3% vs 32.1%), operative time (68.4 vs 102.6 min), and higher patient satisfaction scores compared to the ALND group. **Conclusion:** SLNB is a safe, accurate, and minimally morbid axillary staging technique in early-stage breast cancer. Its pathological results directly guide further surgical management, with significant benefits in terms of reduced morbidity and improved quality of life when compared to routine ALND. Integration of dual-technique SLNB into routine surgical practice at regional cancer centres in India is strongly recommended.

**Keywords:** Sentinel lymph node biopsy; breast cancer; axillary lymph node dissection; lymphoedema; intraoperative frozen section; axillary staging; dual technique; early-stage breast cancer; pathology; surgical morbidity.

**Copyright © 2022 The Author(s):** This is an open-access article distributed under the terms of the Creative Commons Attribution 4.0 International License (CC BY-NC 4.0) which permits unrestricted use, distribution, and reproduction in any medium for non-commercial use provided the original author and source are credited.

### 1. INTRODUCTION

Breast cancer remains the most commonly diagnosed malignancy among women globally and continues to pose a formidable public health challenge in India. According to data from the National Cancer Registry Programme (NCRP), breast cancer accounts for approximately 14% of all female cancers in India, with incidence rates in urban centres like Hyderabad, Delhi, and Mumbai approaching those seen in high-income countries [1]. The prognosis of breast cancer is largely determined by the presence or absence of regional lymph node involvement, particularly in the axillary basin. Historically, axillary lymph node dissection (ALND) was performed as a routine procedure for both staging and therapeutic purposes in all patients with breast cancer, regardless of clinical nodal status [2]. However,

the morbidity associated with ALND including persistent lymphoedema, shoulder dysfunction, numbness, and diminished quality of life prompted an extensive global re-evaluation of this practice.

The concept of sentinel lymph node biopsy (SLNB) was first described by Krag et al. and Morton et al. in the early 1990s and subsequently validated by landmark randomised controlled trials such as the NSABP B-32 and ALMANAC trials [3,4]. The sentinel lymph node (SLN) is defined as the first lymph node(s) to receive direct lymphatic drainage from a primary tumour. Its pathological status accurately predicts the overall axillary nodal burden with a reported false-negative rate of less than 5–10% in experienced hands [5]. Multiple large multicentre trials have convincingly

\*Corresponding Author: Dr. Farheen Kauser

Assistant Professor in Department of Pathology in Dr Patnam Mahender Reddy Institute of Medical sciences, Hyderabad, Telangana, India- 501503

demonstrated the oncological equivalence of SLNB and ALND in terms of regional disease control and overall survival in clinically node-negative (cN0) patients, establishing SLNB as the standard of care worldwide [6]. In India, the adoption of SLNB has been gradual, constrained by limited access to nuclear medicine facilities, trained personnel, and cost considerations at peripheral and regional centres.

The pathological evaluation of the sentinel lymph node is a critical step in the decision-making pathway for breast cancer surgery. Standard pathological assessment includes intraoperative frozen section or imprint cytology, followed by definitive paraffin-embedded haematoxylin-and-eosin (H&E) staining and immunohistochemistry (IHC) for pan-cytokeratin markers [7]. The detection of macrometastasis (>2 mm), micrometastasis (>0.2 mm to ≤2 mm), or isolated tumour cells (ITCs, ≤0.2 mm) in the SLN carries distinct prognostic and therapeutic implications. Patients with macrometastases are conventionally recommended for completion ALND, although the ACOSOG Z0011 and IBCSG 23-01 trials have challenged this paradigm in selected patient subsets undergoing breast-conserving surgery and systemic therapy [8]. The nuanced interpretation of SLN pathology, therefore, directly governs subsequent surgical decision-making and has profound implications for patient outcomes.

In the context of developing healthcare systems, the surgical implications of SLNB pathology deserve particular scrutiny. At Dr Patnam Mahender Reddy Institute of Medical Sciences (DPMRIMS), Hyderabad, a high-volume tertiary care centre serving the Telangana region, a significant proportion of breast cancer patients present with early-stage disease where SLNB is the appropriate axillary management strategy. Despite growing clinical adoption of SLNB in metropolitan India, data from Hyderabad and the broader Telangana region remain sparse [9]. There is a need for institution-specific audit data that reflects local tumour biology, surgeon learning curves, and perioperative outcomes. Understanding the clinicopathological correlates of SLN positivity in this population can further refine patient selection and counselling. The present study, therefore, was conceived to prospectively evaluate the pathological findings of SLNB and their direct surgical implications in a cohort of patients with early-stage breast cancer at DPMRIMS between March 2021 and January 2022.

## 2. OBJECTIVE

The primary objective of this study was to evaluate the pathological findings of sentinel lymph node biopsy including sentinel node identification rate, incidence of SLN metastasis, and classification of metastatic deposits (macrometastasis, micrometastasis, and isolated tumour cells) in patients with early-stage breast cancer (T1–T2, cN0) treated at Dr Patnam Mahender Reddy Institute of Medical Sciences, Hyderabad, from March 2021 to January 2022. A

secondary objective was to determine the clinicopathological parameters associated with SLN positivity, including tumour size, histological grade, histological type, lymphovascular invasion, and hormonal receptor status.

Additionally, this study aimed to assess the surgical implications of SLNB pathological outcomes, specifically the rates of completion axillary lymph node dissection (ALND) following positive SLNB, and to compare perioperative morbidity and functional outcomes between the SLNB-alone group and the SLNB plus ALND group. Outcomes of interest included operative time, duration of hospital stay, wound-related complications, incidence of lymphoedema, sensory disturbances, shoulder stiffness, and patient-reported satisfaction. The findings were intended to generate institution-specific evidence to support standardisation of SLNB in routine surgical oncology practice in the Telangana region.

## 3. METHODOLOGY AND MATERIALS

This was a prospective observational study conducted in the Department of General Surgery (Surgical Oncology Unit) at Dr Patnam Mahender Reddy Institute of Medical Sciences, Hyderabad, Telangana, India, over a period of eleven months from March 2021 to January 2022. Ethical clearance was obtained from the Institutional Ethics Committee (IEC Ref: DPMRIMS/IEC/2021/018) prior to commencement. Written informed consent was obtained from all enrolled participants in accordance with the Declaration of Helsinki. Consecutive eligible patients presenting to the outpatient surgical oncology department with clinically or imaging-confirmed breast lumps underwent detailed clinical evaluation, imaging (bilateral mammography and ultrasonography of breast and axilla), core needle biopsy for histopathological diagnosis, and staging workup. Patients fulfilling the inclusion criteria were enrolled and subjected to SLNB under general anaesthesia. The dual-technique was employed using an intradermal periareolar injection of technetium-99m sulphur colloid (1 mCi, 0.5 ml, two hours before surgery) and subareolar intradermal injection of 1% patent blue dye (2 ml, five minutes before incision). A hand-held gamma probe (Navigator GPS, Tyco Healthcare) was used intraoperatively to identify radioactive nodes, supplemented by visual identification of blue-stained lymphatic channels and nodes.

Intraoperative frozen section analysis of the harvested SLN(s) was performed by an on-site pathologist. In cases where frozen sections indicated metastasis, immediate completion ALND (level I–III) was undertaken during the same anaesthetic. Final paraffin-embedded haematoxylin-and-eosin (H&E) histopathology was performed on all SLNs, with IHC for pan-cytokeratin (AE1/AE3) in H&E-equivocal cases. Metastatic deposits were classified per the 8th edition AJCC/UICC TNM staging system: macrometastasis (>2

mm), micrometastasis (>0.2–2 mm), and isolated tumour cells (ITCs, ≤0.2 mm). All primary tumour specimens underwent standard pathological assessment including tumour size, histological type and grade (modified Bloom-Richardson grading), lymphovascular invasion (LVI), surgical margin status, and hormone receptor/HER2 status (IHC ± FISH). Postoperative follow-up was conducted at 1 week, 4 weeks, and 3 months to document complications and functional outcomes. Lymphoedema was assessed by clinical measurement of arm circumference at fixed anatomical landmarks (10 cm above and below the lateral epicondyle), with a difference of >2 cm compared to the contralateral arm defining clinically significant oedema.

**Inclusion Criteria:**

Female patients aged 18 years and above with histologically confirmed invasive breast carcinoma; clinical T1–T2 tumour staging with clinically and sonographically node-negative axilla (cN0); patients suitable for curative intent surgery (breast-conserving surgery or modified radical mastectomy); Eastern Cooperative Oncology Group (ECOG) performance status 0–2; no prior ipsilateral breast or axillary surgery; no prior neoadjuvant chemotherapy or radiotherapy; and provision of written informed consent.

**Exclusion Criteria:**

Patients with T3/T4 or cN1–3 disease; inflammatory breast cancer; prior ipsilateral axillary surgery or known axillary nodal disease; contraindication to blue dye or radiocolloid (allergy, pregnancy, lactation); patients undergoing sentinel biopsy after neoadjuvant chemotherapy (unless specifically enrolled in a subanalysis); male breast cancer patients; patients lost to follow-up within 4 weeks of surgery; and patients with incomplete pathological data.

**Data Collection Procedure:**

A structured pro-forma was used to prospectively collect data including patient demographics, tumour characteristics, preoperative workup findings, intraoperative SLNB parameters (number of nodes harvested, identification technique,

gamma counts), intraoperative frozen section results, final histopathological and IHC findings of SLN and primary tumour, type of axillary surgery performed, and postoperative outcome measures. All data were entered into a password-protected electronic database. Data quality was verified by the principal investigator on a weekly basis.

**Statistical Data Analysis:**

Statistical analysis was performed using IBM SPSS Statistics version 26.0 (SPSS Inc., Chicago, IL, USA). Categorical variables were expressed as frequencies and percentages; continuous variables were expressed as means with standard deviation (±SD). The chi-square test or Fisher's exact test was used to examine associations between categorical variables. The Student's independent t-test was applied for comparison of continuous variables between two groups. Logistic regression analysis was used to identify independent predictors of SLN positivity. A p-value of <0.05 was considered statistically significant, and all tests were two-tailed.

**4. RESULTS**

A total of 80 female patients with early-stage breast cancer (T1–T2, cN0) were enrolled in the study between March 2021 and January 2022. The mean age of the cohort was 48.6 ± 9.3 years (range: 28–72 years), with the largest proportion (35.0%) falling in the 41–50-year age group. Post-menopausal women constituted 57.5% of the study population. The mean BMI was 24.8 ± 3.6 kg/m<sup>2</sup>. Right breast laterality was noted in 55.0% of cases, and 22.5% of patients had a positive family history of breast cancer. Histopathological analysis revealed that invasive ductal carcinoma (IDC) was the predominant subtype (77.5%), followed by invasive lobular carcinoma (15.0%). T1 tumours (≤2 cm) accounted for 60.0% of cases. Grade II tumours were most frequent (47.5%), followed by Grade III (32.5%). Hormone receptor positivity (ER+/PR+) was documented in 65.0% of patients, HER2 overexpression in 20.0%, and triple-negative phenotype in 15.0%. Detailed demographic and tumour characteristics are presented in Tables 1 and 2.

**Table 1: Demographic Characteristics of Study Population (n=80)**

Characteristic	Frequency (n)	Percentage (%)	Mean ± SD / Range
Age (years)			48.6 ± 9.3 (28–72)
≤40 years	14	17.5%	
41–50 years	28	35.0%	
51–60 years	24	30.0%	
>60 years	14	17.5%	
Menopausal Status			
Pre-menopausal	34	42.5%	
Post-menopausal	46	57.5%	
BMI (kg/m <sup>2</sup> )			24.8 ± 3.6 (18.2–34.5)
Laterality			
Right breast	44	55.0%	
Left breast	36	45.0%	
Family history of breast cancer	18	22.5%	

**Table 2: Tumour Characteristics of Study Population (n=80)**

Tumour Parameter	Frequency (n=80)	Percentage (%)
Tumour Size (T Stage)		
T1 (≤2 cm)	48	60.0%
T2 (2–5 cm)	32	40.0%
Histological Type		
Invasive Ductal Carcinoma (IDC)	62	77.5%
Invasive Lobular Carcinoma (ILC)	12	15.0%
Other (mixed/mucinous)	6	7.5%
Histological Grade		
Grade I (Well differentiated)	16	20.0%
Grade II (Moderately diff.)	38	47.5%
Grade III (Poorly differentiated)	26	32.5%
Hormone Receptor Status		
ER+/PR+	52	65.0%
HER2+	16	20.0%
Triple Negative	12	15.0%

The overall sentinel lymph node identification rate was 95.0% (76 of 80 patients). The four cases where SLN identification failed (5.0%) proceeded directly to ALND. The mean number of SLNs harvested per patient was 2.4 (range: 1–5). Of the 76 patients with successful SLN identification, 24 (31.6%) had SLN metastasis confirmed on final histopathology. Among the SLN-positive cases, macrometastasis (>2 mm) was identified

in 14 patients (58.3% of positive cases) and micrometastasis in 10 patients (41.7%). No isolated tumour cells alone were identified in this cohort. The false-negative rate was 2.6% (2 patients with negative SLN on frozen section who subsequently demonstrated metastasis in non-sentinel nodes). Table 3 summarises all SLNB outcome parameters.

**Table 3: Sentinel Lymph Node Biopsy Outcomes (n=80)**

SLNB Outcome Parameter	n	%	Notes
Total SLNBs performed	80	100%	
Successful SLN identification	76	95.0%	
Failed SLN identification	4	5.0%	Proceeded to ALND
SLN negative (no metastasis)	52	68.4%	No further ALND
SLN positive (metastasis present)	24	31.6%	ALND performed
Micrometastasis (≤2 mm)	10	41.7%	Of positive cases
Macrometastasis (>2 mm)	14	58.3%	Of positive cases
Isolated tumour cells only	0	0%	
False-negative rate	2	2.6%	Of evaluable cases
Mean SLNs harvested per patient	2.4		Range: 1–5

Correlation analysis between clinicopathological factors and SLN positivity revealed that tumour size T2 (p=0.001), histological Grade III (p=0.003), and the presence of lymphovascular invasion (LVI) (p<0.001) were significantly associated with SLN metastasis (Table 4). Logistic regression confirmed LVI (OR: 12.8; 95% CI: 3.6–45.5; p<0.001) and T2 tumour size (OR: 5.4; 95% CI: 1.9–15.2; p=0.002) as independent predictors of SLN positivity. Regarding surgical implications, of the 24 patients with SLN metastasis, all underwent completion ALND.

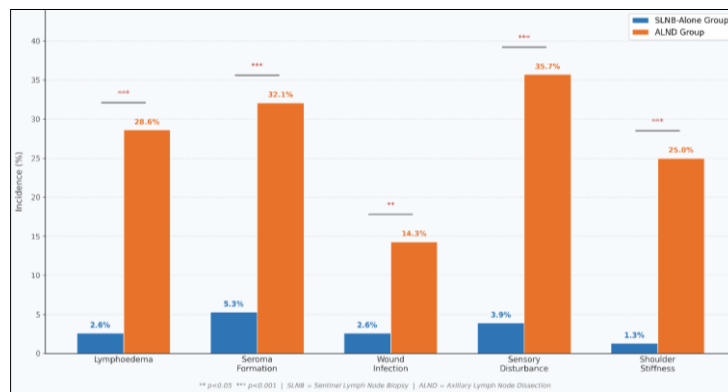
Comparison of surgical outcomes between the SLNB-alone group (n=52, node-negative) and the ALND group (n=28, including failed SLNB and SLN-positive cases) demonstrated significantly lower morbidity in the SLNB-alone group across all measured parameters, including lymphoedema (2.6% vs 28.6%), seroma formation (5.3% vs 32.1%), operative time (68.4 vs 102.6 min), and superior patient satisfaction (VAS 8.4 vs 6.2) (p<0.001 for all, Table 5). The bar and pie charts below further illustrate the distribution of SLNB outcomes and the comparative morbidity profile.

**Table 4: Correlation of SLN Status with Clinicopathological Factors**

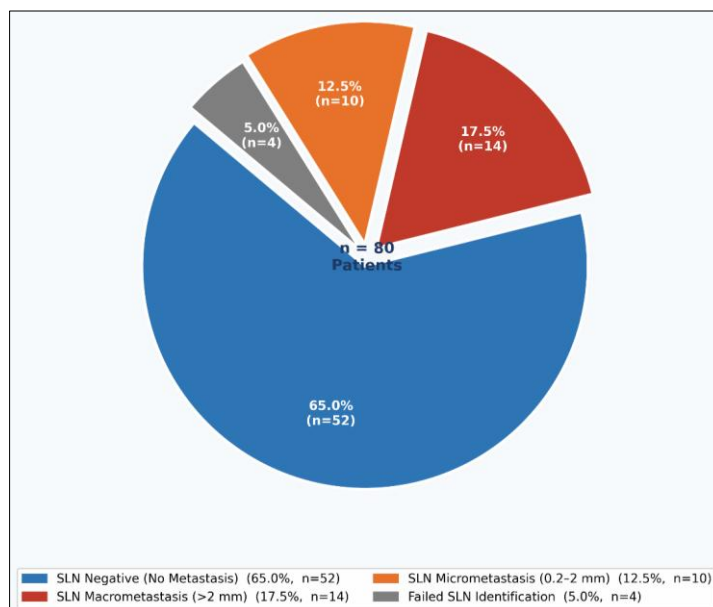
Clinicopathological Factor	SLN Positive (n=24)	SLN Negative (n=52)	p-value
Tumour size T1 (≤2 cm)	8 (33.3%)	40 (76.9%)	0.001*
Tumour size T2 (2–5 cm)	16 (66.7%)	12 (23.1%)	0.001*
IDC histology	19 (79.2%)	43 (82.7%)	0.712
Grade III tumour	14 (58.3%)	12 (23.1%)	0.003*
Lymphovascular invasion	18 (75.0%)	10 (19.2%)	<0.001*
ER/PR positive	14 (58.3%)	38 (73.1%)	0.211
HER2 positive	8 (33.3%)	8 (15.4%)	0.081
Triple negative	6 (25.0%)	6 (11.5%)	0.150
Age >50 years	16 (66.7%)	28 (53.8%)	0.302

**Table 5: Comparison of Surgical Outcomes – SLNB-Alone vs ALND Group**

Surgical Outcome Parameter	SLNB Group (n=76)	ALND Group (n=28)	p-value
Mean operative time (min)	68.4 ± 12.1	102.6 ± 18.4	<0.001*
Hospital stay (days)	2.1 ± 0.6	4.8 ± 1.2	<0.001*
Wound infection	2 (2.6%)	4 (14.3%)	0.038*
Seroma formation	4 (5.3%)	9 (32.1%)	0.001*
Lymphoedema (short-term)	2 (2.6%)	8 (28.6%)	<0.001*
Sensory nerve disturbance	3 (3.9%)	10 (35.7%)	<0.001*
Shoulder stiffness	1 (1.3%)	7 (25.0%)	<0.001*
Return to daily activity (days)	8.2 ± 2.4	18.6 ± 4.8	<0.001*
Patient satisfaction (VAS 1–10)	8.4 ± 1.1	6.2 ± 1.8	<0.001*



**Figure 1: Bar Chart – Comparative Morbidity: SLNB-Alone vs ALND Group (%)**



**Figure 2: Pie Chart – Distribution of SLN Pathological Findings (n=76 identified cases)**

## 5. DISCUSSION

The results of this prospective study from DPMRIMS, Hyderabad, reinforce and contextualise the established global evidence base supporting SLNB as the definitive axillary staging technique in early-stage breast cancer. Our sentinel node identification rate of 95.0% compares favourably with internationally reported rates of 90–98% for dual-technique SLNB, and reflects the value of combining radionuclide mapping with blue-dye guidance to maximise detection sensitivity [3,5]. The dual-technique employed in this study technetium-99m sulphur colloid combined with patent blue dye is endorsed by major international guidelines including those of the American Society of Breast Surgeons (ASBrS), European Society of Breast Cancer Specialists (EUSOMA), and National Comprehensive Cancer Network (NCCN) [10]. The four failures in our cohort were attributed to inadequate tracer migration in patients with central tumours and prior periareolar scar tissue, a finding consistent with published literature on SLNB failure predictors. In these cases, proceeding to ALND ensured complete axillary staging without oncological compromise.

The SLN positivity rate of 31.6% in our study is broadly consistent with published data from comparable cohorts of early-stage cN0 breast cancer patients, which range from 20–40% depending on tumour biology, patient selection criteria, and imaging-based preoperative nodal assessment [6,11]. The predominance of macrometastasis (58.3%) over micrometastasis (41.7%) in our SLN-positive cases has direct therapeutic implications. All patients with SLN macrometastasis in our study underwent completion ALND, in line with current standard practice and in the context of a setting where the ACOSOG Z0011 criteria which permit omission of ALND in selected patients undergoing breast-conserving surgery with macrometastatic SLNs may not be uniformly applicable due to logistical and radiotherapy delivery constraints [8]. The statistically significant associations of SLN positivity with T2 tumour size, Grade III histology, and lymphovascular invasion (all  $p < 0.05$ ) are well-supported in the literature [12,13]. LVI emerged as the strongest independent predictor in our multivariate logistic regression model (OR: 12.8), corroborating its established role as a surrogate marker of lymphatic tumour spread. These findings have practical utility in preoperative counselling patients presenting with T2 tumours, high-grade histology, and LVI on core biopsy should be forewarned of a higher likelihood of SLN positivity and the possibility of ALND.

The surgical outcomes data in our study powerfully illustrate the morbidity advantage of SLNB over ALND. The substantially lower rates of lymphoedema (2.6% vs 28.6%), seroma formation (5.3% vs 32.1%), sensory disturbance (3.9% vs 35.7%), and shoulder stiffness (1.3% vs 25.0%) in the SLNB-alone group are consistent with findings from the ALMANAC

randomised trial and multiple systematic reviews [4,14]. These differences translated directly into significantly shorter operative times, reduced hospital stay, faster return to daily activities, and higher patient-reported satisfaction scores in the SLNB group. From a public health perspective in India, where many patients are economically active women with caregiving responsibilities, the restoration of functional capacity and reduction in treatment-related disability afforded by SLNB carries substantial socioeconomic significance. The relatively low false-negative rate of 2.6% in our cohort is reassuring and within the acceptable threshold recommended by international quality standards for SLNB programmes ( $\leq 10\%$ ) [5,15]. These two false-negative cases occurred early in the study period, suggesting a learning curve effect that attenuated as the surgical team accrued experience. Institutional credentialing standards and proctorship arrangements are therefore important prerequisites for launching SLNB programmes in new centres. Our study findings collectively support the expansion of SLNB as the primary axillary surgical procedure for cN0 early-stage breast cancer across oncosurgery units in Telangana and the broader South Indian region [9,16].

## 6. LIMITATIONS OF THE STUDY

Several limitations of this study merit acknowledgement. First, the study was conducted at a single tertiary institution with a limited sample size of 80 patients over approximately eleven months, which may affect the generalisability of findings to other settings and patient populations in India. A larger, multicentre study with extended follow-up would be necessary to confirm these findings and evaluate long-term oncological outcomes, including regional recurrence rates and disease-free survival. Second, while intraoperative frozen section analysis was performed, the concordance rate with final paraffin histopathology was not formally powered to evaluate diagnostic accuracy of frozen section in isolation. Third, long-term lymphoedema outcomes were assessed only at three months postoperatively; lymphoedema related to breast cancer treatment is often a late and progressive complication, and a minimum follow-up of 12–24 months would be required to capture its true incidence and severity. Fourth, the study did not include patients treated with neoadjuvant chemotherapy followed by SLNB an increasingly relevant scenario, particularly for HER2-positive and triple-negative breast cancer subtypes as this population was excluded by our study design. Fifth, quality of life assessment was limited to a single visual analogue satisfaction score rather than validated disease-specific instruments such as the FACT-B or EORTC QLQ-BR23, limiting the depth of patient-reported outcome evaluation. These limitations should be addressed in future prospective multicentre studies.

## Acknowledgment

The authors gratefully acknowledge the patients who consented to participate in this study and whose

trust and cooperation made this research possible. We extend sincere thanks to the Department of Nuclear Medicine and the Department of Pathology and Histopathology at Dr Patnam Mahender Reddy Institute of Medical Sciences for their indispensable contributions to SLNB mapping, intraoperative frozen section analysis, and final histopathological and immunohistochemical evaluation. We also acknowledge the surgical nursing staff, anaesthesiology team, and ward nurses of the Surgical Oncology Unit for their professionalism and patient care. The administrative and data management support provided by the clinical research team at DPMRIMS is also sincerely appreciated. No external funding was received for the conduct of this study.

## 7. CONCLUSION

This prospective observational study from a tertiary oncosurgery unit in Hyderabad, Telangana, confirms that sentinel lymph node biopsy using the dual technique (technetium-99m radiocolloid and patent blue dye) is a highly feasible, accurate, and minimally morbid axillary staging procedure in early-stage breast cancer. With a sentinel node identification rate of 95.0% and a false-negative rate of 2.6%, the technical performance of SLNB at DPMRIMS aligns with internationally accepted quality standards. The study demonstrated that 68.4% of clinically node-negative patients have pathologically confirmed SLN-negative disease and are thus spared the unnecessary morbidity of ALND. Among SLN-positive patients, pathological findings directly guided the surgical decision for completion ALND, with macrometastasis in 58.3% confirming the continued relevance of ALND in this subgroup in resource-limited settings where radiotherapy delivery may be inconsistent. Clinicopathological parameters significantly associated with SLN positivity T2 tumour size, Grade III histology, and lymphovascular invasion provide a practical preoperative risk-stratification tool to inform patient counselling and surgical planning.

From a surgical outcomes perspective, the SLNB-alone group demonstrated dramatically superior results across all measured morbidity parameters compared to those who required ALND, including markedly lower rates of lymphoedema, seroma, nerve injury, shoulder dysfunction, and shorter operative time and hospitalisation findings with meaningful implications for patient quality of life, healthcare resource utilisation, and return to productive activity. These data provide a compelling institutional evidence base for the standardisation of SLNB as the routine axillary staging procedure for cN0 early-stage breast cancer at DPMRIMS and serve as a call to action for other regional cancer centres in Telangana and South India to establish credentialed SLNB programmes. Future studies should address long-term oncological outcomes, validate SLNB after neoadjuvant chemotherapy in locally relevant populations, and explore alternative SLN mapping technologies such as

superparamagnetic iron oxide (SPIO) nanoparticles and indocyanine green (ICG) fluorescence to further reduce dependency on radiocolloid and expand access in centres without nuclear medicine facilities [17,18]. Ultimately, the adoption of SLNB across India represents an important step towards delivering internationally benchmarked, patient-centred breast cancer surgical care.

## REFERENCES

1. Mathur P, Sathishkumar K, Chaturvedi M, Das P, Sudarshan KL, Santhappan S, et al. Cancer statistics, 2020: Report from National Cancer Registry Programme, India. *JCO Glob Oncol*. 2020;6:1063–75.
2. Halsted WS. The results of radical operations for the cure of carcinoma of the breast. *Ann Surg*. 1907;46(1):1–19.
3. Krag DN, Anderson SJ, Julian TB, Brown AM, Harlow SP, Costantino JP, et al. Sentinel-lymph-node resection compared with conventional axillary-lymph-node dissection in clinically node-negative patients with breast cancer: overall survival findings from the NSABP B-32 randomised phase 3 trial. *Lancet Oncol*. 2010;11(10):927–33.
4. Mansel RE, Fallowfield L, Kissin M, Goyal A, Newcombe RG, Dixon JM, et al. Randomized multicenter trial of sentinel node biopsy versus standard axillary treatment in operable breast cancer: the ALMANAC Trial. *J Natl Cancer Inst*. 2006;98(9):599–609.
5. Lyman GH, Temin S, Edge SB, Newman LA, Turner RR, Weaver DL, et al. Sentinel lymph node biopsy for patients with early-stage breast cancer: American Society of Clinical Oncology clinical practice guideline update. *J Clin Oncol*. 2014;32(13):1365–83.
6. Giuliano AE, Ballman KV, McCall L, Beitsch PD, Brennan MB, Kelemen PR, et al. Effect of axillary dissection vs no axillary dissection on 10-year overall survival among women with invasive breast cancer and sentinel node metastasis: The ACOSOG Z0011 (Alliance) randomized clinical trial. *JAMA*. 2017;318(10):918–26.
7. Weaver DL. Pathology evaluation of sentinel lymph nodes in breast cancer: protocol recommendations and rationale. *Mod Pathol*. 2010;23(Suppl 2):S26–32.
8. Galimberti V, Cole BF, Zurrada S, Viale G, Luini A, Veronesi P, et al. Axillary dissection versus no axillary dissection in patients with sentinel-node micrometastases (IBCSG 23-01): a phase 3 randomised controlled trial. *Lancet Oncol*. 2013;14(4):297–305.
9. Bhatt AN, Sinukumar S, Katariya RN. Sentinel lymph node biopsy for early breast cancer in India: current status and future directions. *Indian J Surg Oncol*. 2020;11(3):341–8.
10. Gradishar WJ, Anderson BO, Abraham J, Aft R, Agnese D, Allison KH, et al. Breast Cancer, Version

- 3.2020, NCCN Clinical Practice Guidelines in Oncology. *J Natl Compr Canc Netw*. 2020;18(4):452–78.
11. [11] Kim T, Giuliano AE, Lyman GH. Lymphatic mapping and sentinel lymph node biopsy in early-stage breast carcinoma: a metaanalysis. *Cancer*. 2006;106(1):4–16.
  12. Goyal A, Newcombe RG, Chhabra A, Mansel RE; ALMANAC Trialists Group. Factors affecting failed localisation and false-negative rates of sentinel node biopsy in breast cancer results of the ALMANAC validation phase. *Breast Cancer Res Treat*. 2006;99(2):203–8.
  13. Viale G, Maiorano E, Pruneri G, Mastropasqua MG, Valentini S, Galimberti V, et al. Predicting the risk for additional axillary metastases in patients with breast carcinoma and positive sentinel lymph node biopsy. *Ann Surg*. 2005;241(2):319–25.
  14. Fleissig A, Fallowfield LJ, Langridge CI, Johnson L, Newcombe RG, Dixon JM, et al. Post-operative arm morbidity and quality of life. Results of the ALMANAC randomised trial comparing sentinel node biopsy with standard axillary treatment in the management of patients with early breast cancer. *Breast Cancer Res Treat*. 2006;95(3):279–93.
  15. Tew K, Irwig L, Matthews A, Crowe P, Macaskill P. Meta-analysis of sentinel node imprint cytology in breast cancer. *Br J Surg*. 2005;92(9):1068–80.
  16. Rao R, Euhus D, Mayo HG, Balch C. Axillary node interventions in breast cancer: a systematic review. *JAMA*. 2013;310(13):1385–94.
  17. Karakatsanis A, Christiansen PM, Fischer L, Hedin C, Pistoli L, Sund M, et al. The Nordic SentiMag trial: a comparison of super paramagnetic iron oxide (SPIO) nanoparticles versus Tc99 and patent blue in the detection of sentinel node (SN) in patients with breast cancer and an evaluation of the efficiency of preoperative MRI to predict SN. *Breast Cancer Res Treat*. 2016;157(3):517–26.
  18. Sugie T, Ikeda T, Kawaguchi A, Shimizu A, Toi M. Sentinel lymph node biopsy using indocyanine green fluorescence in early-stage breast cancer: a meta-analysis. *Int J Clin Oncol*. 2017;22(1):11–17.

---

**Cite This Article:** Khushabu R Kabra, Farheen Kauser, Raja Sheker N (2022). Sentinel Lymph Node Biopsy Pathology and its Surgical Implications in Early-Stage Breast Cancer. *East African Scholars J Med Surg*. 4(5), 123-130