

## Original Research Article

# Management of Pyeloureteral Junction Syndrome in the Pediatric Surgery Department of the Mali Hospital in Bamako

Sidibe, S<sup>1\*</sup>, Kouyaté, M<sup>2</sup>, Diallo, K. W<sup>3</sup>, D, Sanata, S<sup>4</sup>, Coulibaly, Y<sup>5</sup><sup>1</sup>Pediatric Surgery Department of the Mali Hospital<sup>2</sup>Department of Pediatric Surgery Fousseyni Daou Hospital in Kayes<sup>3</sup>Mali Hospital Pediatrics Service<sup>4</sup>Mali Hospital Public Health Service<sup>5</sup>Pediatric Surgery Department of the CHU Hôpital Gabriel Touré**Article History**

Received: 30.10.2022

Accepted: 07.12.2022

Published: 20.12.2022

**Journal homepage:**<https://www.easpublisher.com>**Quick Response Code**

**Abstract: Introduction:** The pyelo-ureteral junction syndrome is defined by a dilation of the renal pelvis and the calyces with a downstream ureter of normal caliber. It is a fairly frequent pathology often of congenital cause whose diagnosis can be ante-natal or post-natal thanks to ultrasound. The treatment is surgical especially if there are clinical manifestations. The objective of this work is to study in general the pyelo-ureteral junction syndrome in the pediatric surgery department of the Mali hospital. **Material and Methods:** This was a prospective study which took place at the Mali hospital from May 2018 to April 2021. This study included all patients aged 0 to 15 who were operated on for pyelo-ureteral junction. **Results:** During the 3-year study period, we collected 12 cases of pyelo-ureteral junction syndrome. The average age was 3 years with extremes of 20 days and 14 years. All patients had an abdominal mass accompanied by abdominal pain in 83.3% of cases. Dehydration was present in 66.66% of patients. The attack of the left kidney was predominant is 66.66% of the patients, in only one patient the expectation was bilateral. Serum creatinine was normal in all patients. Cytobacteriological examination of urine found 2 cases of Echerichia coli infections. 10 pyeloplasties and 2 nephrectomies were performed with simple postoperative course. **Conclusion:** The pyeloureteral junction syndrome is a frequent pathology in the literature but not very frequent in our daily practice. Most of our diagnoses are made post natively. It is not very symptomatic, mainly affecting male infants. Ultrasound and Uro scanner have a very important role in the exploration of this pathology. Open-air surgery is the technique of choice in our context.

**Keywords:** Pyelo-ureteral junction syndrome, child, hospital in Mali.

**Copyright © 2022 The Author(s):** This is an open-access article distributed under the terms of the Creative Commons Attribution 4.0 International License (CC BY-NC 4.0) which permits unrestricted use, distribution, and reproduction in any medium for non-commercial use provided the original author and source are credited.

## INTRODUCTION

The syndrome of the pyelo-ureteral junction (PUJS) also called essential hydronephrosis, or primary hydronephrosis is defined as a urodynamic disorder of evacuation of the upper excretory pathway with pyelocalicielle distension, upstream of a functional or organic obstacle [1]. It is the most common obstructive uropathy in newborns and affects about 0.2% of live births with a male predominance [2]. In developed countries, systematic antenatal screening has profoundly modified the clinical profile of this pathology [3]. The clinical manifestations remain the circumstances in which the disease is discovered in developing countries. The standard treatment for ureteropelvic junction syndrome is based on the principles of resection anastomosis, as stated by Kuss,

Andersson and Hynes [4]. In Mali, few studies have addressed the issue, hence the interest for us to review the cases of SJPU treated in the service in order to improve its management.

## MATERIALS AND METHODS

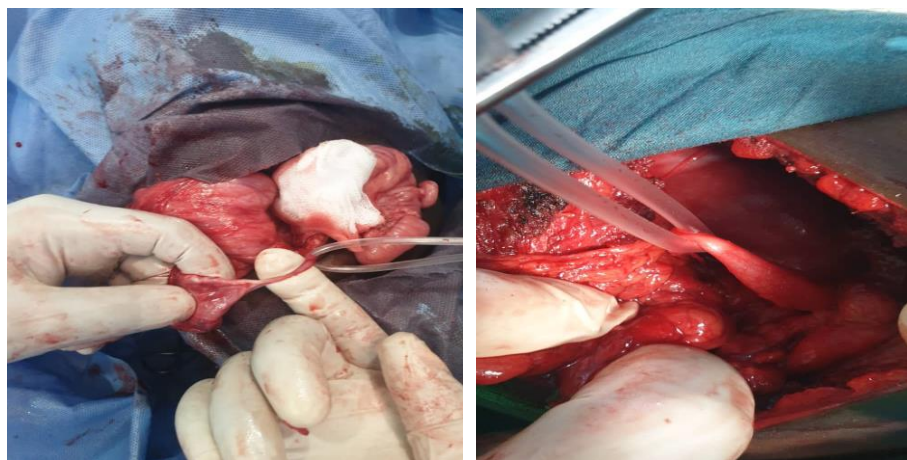
This was a 3-year prospective and descriptive study (May 2018 to April 2021) on all children with ureteropelvic junction syndrome and cared for in the department during the study period. Were retained in the study the patients who were operated and who benefited from a follow-up. For each case, the sex, age, clinical and paraclinical picture, treatment methods and postoperative course were studied. Therapeutic gestures consisted of pyeloplasty, nephrectomy in case of mute kidney. Antibiotic therapy based on 3rd generation

cephalosporin was administered pending isolation of the germ and the result of the antibiogram. The average follow-up of our patients was one year.

## RESULT

In 3 years we have collected 12 cases, an annual average of 4 cases. The average age was 3 years with extremes of 20 days and 14 years. The sex ratio was 3.5. All our patients were admitted to the outpatient department with abdominal bloating associated with abdominal pain except one (1) who was admitted in the context of abdominal trauma with hemoperitoneum. The diagnosis was antenatal in 2 cases (16.66%). Abdominal pain was noted in 10 patients (83.33%). dehydration was the main general sign found in 8 cases

out of 12. An abdominal mass was found in all our patients. Left side involvement was predominant in 8 cases (66.66%). It was bilateral in 1 case (8.33%). All our patients have benefited from an ultrasound and a Uro-scanner. Renal function evaluated by serum creatinine was normal in all our patients. All patients underwent a cytobacteriological examination of urine (ECBU) and 2 patients developed a urinary tract infection with *Escherichia coli* who received antibiotic therapy depending on the antibiogram before their surgery. Pyeloplasty was performed in 10 patients (83.33%) and 2 nephrectomies for non-functional kidney with absence of parenchyma. The postoperative course was simple for all our patients and all were discharged on their 7th day of hospitalization.



Two cases of pyelo-ureteral syndrome operated on in our department

## DISCUSSIONS

PUPS is the most common obstructive uropathy. We recorded a frequency of 4 cases/year, this result differs from those found by SAYAD 10 cases/year [5] and JAIDANE [6] which could be explained by the management of this pathology in other departments. The PUS is most often congenital and the diagnosis is made very early before 5 years according to the literature [7, 8]. The average age of our patients is 3 years. The diagnosis was made antenatally in two of our patients thanks to antenatal ultrasound. This result corroborates that of Touré *et al* in Mali who finds in his study 14.3% [10]. This low rate of antenatal diagnosis could be explained by the insufficiency of prenatal consultation and by the realization of antenatal ultrasounds by practitioners non-specialists in most cases. Male predominance has been reported by several authors [1, 5, 9]. Frequent involvement of the left kidney is reported in the literature, which is the case in our study with 66.66%. Ultrasound and Uro scanner were performed in all our patients unlike the study by Touré *et al.*, [10] where the scanner was only performed in 20% of cases. This difference is explained by the easy access of the scanner in our structure.

Pyeloplasty according to Kuss Andersonhynes was performed in 8 of our patients, i.e. 66.66%. This technique is recognized as being the reference and the most effective [12]. Other techniques have been practiced by certain authors Sayad [3] performed open ureterocalicelle anastomosis. Moore [13] and Tanchoux [14] instead performed laparoscopy in 97% and 91% respectively. This difference in the realization of certain techniques such as laparoscopy is explained by the absence of laparoscopy in our structure and on the other hand it is assumed that the KUSS ANDERSON HYNES pyeloplasty is the best. We performed two nephrectomies for non-functional kidney. This rate is comparable to that of the literature [1, 3, 8] and Touré *et al.*, [10].

We did not record postoperative complications or deaths, unlike the study by Touré *et al*, which recorded 8.6% morbidity and 2.8% death. This difference may be explained by the size of our workforce, which was lower.

## CONCLUSION

The pyeloureteral junction syndrome is a frequent pathology in the literature but not very frequent in our daily practice. Most of our diagnoses are

made post natally. It is not very symptomatic, mainly affecting male infants. Ultrasound and Uro scanner have a very important role in the exploration of this pathology. Open-air surgery is the technique of choice in our context.

## ACKNOWLEDGEMENTS

We would like to thank Dr. Aboubacar Sidiki Thissé KANÉ, Dental Surgeon Periodontist for his help in preparing this document.

## REFERENCES

1. Diarra, A. A. (2006). Syndrome de la jonction pyélo-urétérale au service d'Urologie de l'Hôpital du Point G. Thèse méd. Bamako, (06M163). 2V.
2. Grapin-Dagorno, C. (2008). Prise en charge précoce des anomalies de la jonction pyélo urétérale. 102<sup>e</sup> Congrès de l'Association Française d'Urologie, Paris, 19(11), p 15-17.
3. Hatem, R., Habiba, M., Amine, A., MOHANIED, S., & MOHSEN, A. (2006). Rupture post-traumatique d'un syndrome de la jonction pyelo-ureterale meconnu: A propos d'une observation. *Tunisie médicale*, 84(2), 131-134.
4. Anderson, J. C., & Hynes, W. (1949). Retrocaval Ureter: A Case diagnosed pre-operatively and treated successfully by a Plastic Operation. *British journal of urology*, 21(3), 209-214.
5. Sayad, L. A. (2000). Syndrome de jonction pyélo-urétérale à propos de 40 cas. Thèse med. Marrakech, 2010; n° 137. 4. Jaidane, M. Anomalies de la jonction pyélo-urétérale à propos de 219 cas. Thèse med. Sousse.
6. Jaidane, M. (2000). Anomalies de la jonction pyélo-urétérale à propos de 219 cas. Thèse med. Sousse.
7. Galifer, R. B., Veyrac, C., & Faurous, P. Les anomalies congénitales de la jonction pyélo-urétérale chez l'enfant. Etude multicentrique de 985 observations chez 883 enfants. *Ann Uro*, 41987 (21). p: 2416249.
8. Michel, A., Monod, P., Descotes, J. L., Rambeaud, J. J., Bourdat, G., & Faure, G. (1991). Surgical treatment for ureteropelvic junction syndrome in infants and children (report of 73 cases). *Progres en Urologie: Journal de L'association Francaise D'urologie et de la Societe Francaise D'urologie*, 1(6), 987-999.
9. Mouh Mouh, L. (2010). Le syndrome de la jonction pyélo-urétérale chez l'enfant (A propos de 26 cas). Thèse med. Rabat.
10. Amadou, I., Coulibaly, Y., Coulibaly, O. M., Keita, M., Coulibaly, M. T., Coulibaly, Y., ... & Diallo, G. (2018). Syndrome de la Jonction Pyélo-Urétérale: Aspects Cliniques et Thérapeutiques au CHU Gabriel Toure. *Health Sciences and Disease*, 19(3). Available at [www.hsd-fmsb.org](http://www.hsd-fmsb.org)
11. Audry G, DE Vries P, Bonnard A. Particularités du traitement de l'anomalie de la jonction pyélo-urétérale chez l'enfant. EMC (Elsevier SAS, Paris), Techniques chirurgicales-Urologie, 41-086, 2006
12. Audry, G. D. E., Vries, P., Bonnard, A. (2006). Particularités du traitement de l'anomalie de la jonction pyélo-urétérale chez l'enfant. EMC (Elsevier SAS, Paris), Techniques chirurgicales-Urologie, 41-086.
13. Moore, R. G., Averch, T. D., Schulam, P. G., Adams, J. B., Chen, R. N., & Kavoussi, L. R. (1997). Laparoscopic pyeloplasty: experience with the initial 30 cases. *The Journal of urology*, 157(2), 459-462.
14. Tanchoux, C. (2014). Syndrome de la jonction pyélo-urétérale chez l'adulte 110 malades, 17 octobre 2014. Faculté de médecine de TOURS.

**Cite This Article:** Sidibe, S, Kouyaté, M, Diallo, K. W, D, Sanata, S, Coulibaly, Y (2022). Management of Pyloureteral Junction Syndrome in the Pediatric Surgery Department of the Mali Hospital in Bamako. *East African Scholars J Med Surg*, 4(11), 251-253.