

Research Article

Sonographic Findings of Non Traumatic Acute Abdomen in Pediatric Patients at Mulago Hospital

Thokozani Sibanda*¹, Rosemary K. Byanyima², Samuel Bugeza³ & John Sekabira⁴¹Radiology Senior House Officer, Mulago National Referral hospital, Uganda²Senior Consultant Radiologist, Mulago National Referral hospital, Uganda³Radiologist, Lecturer, Makerere College of Health Sciences, Uganda⁴Consultant Paediatric Surgeon, Mulago National Referral Hospital, Uganda**Article History**

Received: 16.04.2020

Accepted: 21.04.2020

Published: 25.04.2020

Journal homepage:<https://www.easpublisher.com/easjrit>**Quick Response Code**

Abstract: *Background:* This study set out to (1) describe the ultrasound features of non traumatic acute abdomen (NTA) among paediatric patients at Mulago National Referral Hospital (MNRH); (2) to describe the common clinical presentations of NTA paediatric emergencies at MNRH; (3) to relate the clinical features with ultrasound findings and lastly (4) to relate the ultrasound findings with the final diagnosis (whether surgically or medically managed). *Materials and methods:* A prospective cross sectional study was carried out. Eighty-seven paediatric patients (12 years and below) who were sent for ultrasound scan of the abdomen following an initial clinical impression of acute abdomen were scanned at MNRH radiology department between March 2015 and March 2016. Linear and a curvilinear probes from a Samsung Medison Sonoace R7 Ultrasound machine model 2013 were used. To answer the research questions, categorical variables were summarized using proportions. Continuous variables were summarized by computing the median and range. *Results:* The commonest clinical presentations of children with NTA besides abdominal pain were fever (69%) and vomiting (67%). The patients who presented with vomiting were more likely to have positive US findings. The commonest ultrasound findings were mesenteric lymphadenitis 18 (21.1%), ascites 14 (16.8%) and pneumoperitonium (10.6%). The most common US diagnosis in infants was intussusception 6 (29%), while children 1-3 years were mostly diagnosed with mesenteric lymphadenitis 3(27%) and ascites 3(27%), those aged between 4-7 years 6 (40%); 8-12 years 7 (25%) were mostly diagnosed with mesenteric lymphadenitis. *Conclusion:* The commonest ultrasound findings were mesenteric lymphadenitis, ascites and pneumoperitonium. The most common US diagnosis in infants was intussusception 6 (29%), while children 1-3 years were mostly diagnosed with mesenteric lymphadenitis 3(27%) and ascites 3(27%), those aged between 4-7 years 6 (40%); 8-12 years 7 (25%) were mostly diagnosed with mesenteric lymphadenitis.

Keywords: Non traumatic acute abdomen, ultrasound, paediatric.

Copyright © 2020 The Author(s): This is an open-access article distributed under the terms of the Creative Commons Attribution **4.0 International License (CC BY-NC 4.0)** which permits unrestricted use, distribution, and reproduction in any medium for non-commercial use provided the original author and source are credited.

INTRODUCTION

Acute abdomen is a worldwide cause for visits to the casualty department. Acute abdomen is a medical emergency which requires urgent and specific diagnosis with some causes needing surgical intervention. The role of emergency management, including investigations, is not to miss these life-threatening ailments and where possible to determine the exact cause (Babcock, D. S. 2002). Worldwide proportion of non-traumatic acute abdomen (NTA) in paediatric patients range from 5.1-8% (Balachandran, B. *et al.*, 2013; & Scholer, S. J. *et al.*, 1996). There is no available data of prevalence of acute abdomen in paediatric patients in Uganda. The number of paediatric patients aged 12 years and below seen at MNRH casualty average about 1800 cases per month. Of those, 1% (20 patients) are cases of NTA.

Ultrasound is an appropriate modality choice for the initial investigating of NTA in paediatric patients because of its availability, non-invasive nature, uses non ionising radiation, can be performed with no need of sedation and its high sensitivity in finding some of the common conditions causing acute abdomen (Khalid, M. *et al.*, 2012). Studies have also shown that use of plain radiography does not yield useful information in most patients presenting with acute abdomen (Mazzei, M. A. *et al.*, 2013).

At MNRH 70% of the paediatric patients who present with acute abdomen undergo both ultrasound and X-ray of the abdomen. There is no clear protocol for the management of these patients. This study therefore set out to describe sonographic findings in NTA abdominal emergencies in paediatrics at MNRH.

The study compared the management plan with the sonographic findings which helps deduce the sensitivity of Ultrasound scanning for the surgically managed patients. The outcome will lay a guideline in future workup of paediatric patients presenting with NTA.

METHODOLOGY

The study was conducted in MNRH casualty and Acute Care Unit in Kampala Uganda from March 2015 to March 2016. The Hospital is a 1,500-bed unit providing tertiary diagnostic, curative, rehabilitative, preventive and teaching services.

A prospective cross sectional study was done. The study population consisted of patients aged 12 years and less presenting at MNRH Casualty and Acute Care Unit with NTA for a duration of 7 days or less. An estimation of 240 patients/ year are seen at Mulago Hospital presenting with NTA. Sample size calculation used Kish and Leslie formula, adjusted for the available sample size to get a sample of 77 patients. Ultimately 85 patients were recruited for the study using consecutive sampling. All the recruited patients parents or guardians consented and the patients aged 7 years and above assented. All patients with NTA who visited casualty were assessed by a paediatric surgery SHO who after a thorough history and clinical examination made a clinical diagnosis and ordered investigations to confirm or rule out a diagnosis. An ultrasound examination was done in the casualty department by the principal investigator, who was a third year radiology resident and images were discussed with two senior radiologist who have been in practice for more than 10 years. An ultrasonographic diagnosis was made on the basis of pathognomic features of the abdominal pathologies. A Samsung Medison Sonoace R7 Ultrasound machine model 2013 Linear(5-12 MHz) and a curvilinear(2-5MHz) probes were used. Patients were followed up to relate the surgical findings with the ultrasound findings. The patients managed medically were followed at day 7 where ultrasound was correlated with clinical findings and treatment response. The independent variables collected were: age, sex, duration of pain, history of pain, other GI symptoms, non GI symptoms. Moderating variables were previous surgery and recent medication. The dependent variable were surgical, final diagnosis and ultrasound findings.

To answer the research questions, categorical variables such as clinical features and various forms of NTA (ultrasound findings) were summarized using proportions. Graphically pie charts and bar charts were used to present the distribution of categorical data. The differences by age group and sex were assessed using the chi square test and the Fisher's exact test. Continuous variables were summarized by computing the median and range.

Some of the limitations of the study were missed patients who had to be rushed to surgery, uncooperative patients and patient's inability to relate their history. Another significant limitation was the lack of intra-op findings to correlate with ultrasound findings in patients who were managed medically.

RESULTS

During the 1 year study period, 85 consecutive patients with NTA underwent abdominal US scan and were recruited for the study. The subject population consisted of 48 (56%) males and 37 (44%) females. The age ranged from 3 days to 12 years and the median age was 6 years. Most of the patients 32 (37.6%) patients were aged between 8-12 years. Ages were rounded off to the nearest whole number, e.g. 3 years 4 months was taken as 3 years. Of all the patients 26 (30.5%) had nonspecific pain whilst 19 (22%) had right iliac fossa pain. The patients unable to localise and or communicate position of pain were grouped as non specific. Excluding abdominal pain, vomiting 59 (69%) and fever 56(67%) were the most cited symptoms. The median duration of symptoms was 4 days. Most of the patient's symptoms had been present for 3-4 days before presentation. Positive ultrasound findings were seen in 89% of the patients. Nine patients had normal US scan findings and were hence considered as having nonspecific abdominal pain.

Following ultrasound evaluation of children aged 12 years and below presenting with NTA at MNRH, the commonest findings were mesenteric lymphadenitis 18 (21.1%), peritonitis 14 (16.8%) and pneumoperitonium 9 (10.6). The causes were grouped according to the age as shown in the Table 1 below.

Table 1: Ultrasound findings by age group of patients

Radiological findings	Age Group				Total
	< 1 year	1-3 years	4-7 years	8-12 years	
Abdominal Abscess			1(7%)	3(11%)	4(5%)
Pneumoperitonium	3(14%)	1(9%)	3(20%)	2(7%)	9(12%)
Cholecystitis	1(4%)	1(9%)	1(7%)		3(4%)
Cholelithiasis				1(4%)	1(1%)
Dermoid Cyst		1(9%)	1(7%)		2(1%)
Duodenal Atresia	4(20%)				4(5%)
Cystitis				1(4%)	1(1%)
Inguinal Lymphadenopathy		1(9%)			1(1%)
Intussusception	6(29%)				6(8%)

Liver Abscess			1(7%)		1(1%)
Mesenteric Lymphadenitis	1(4%)	2(18%)	4(27%)	5(18%)	13(17%)
Abdominal lymphadenopathy		1(9%)	2(13%)	2(7%)	5(7%)
Necrotising Enterocolitis	1(4%)				1(1%)
Peritonitis	3(14%)	3(27%)	1(7%)	7(25%)	14(18%)
Right Testicular Abscess		1(9%)			1(1%)
Testicular Torsion				1(4%)	1(1%)
Appendiceal Related			1(7%)	5(18%)	6(8%)
Hernia	2(11%)			1(4%)	3(4%)
Total	21(100%)	11(100%)	15(100%)	28(100%)	76(100%)

The most common US diagnosis in infants was intussusception 6 (29%), while children 1-3 years were mostly diagnosed with peritonitis 3(27%) and

mesenteric lymphadenitis 2(18%), those aged between 4-7 years 6 (40%); 8-12 years 7(25%) were mostly diagnosed with peritonitis.

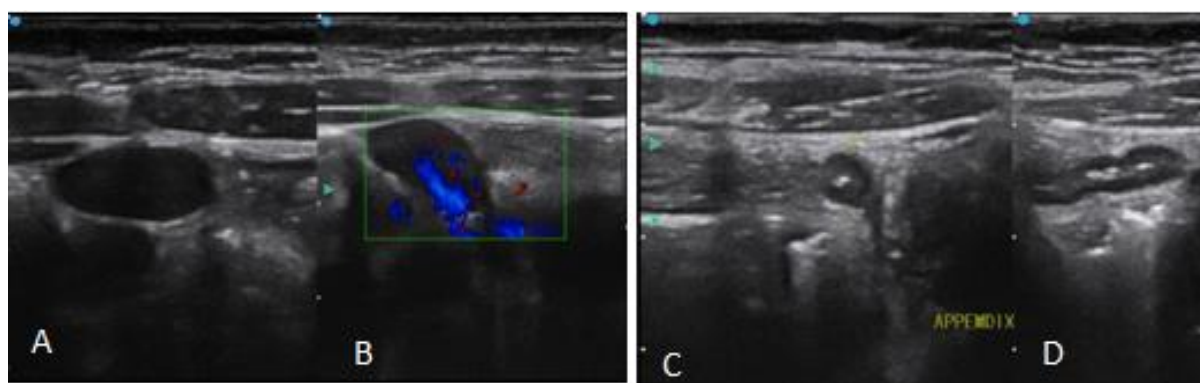


Figure 1 US images in a 7 year old who presented with a 1 day history of RIF pain. **A** and **B** show mesenteric enlarged lymph nodes with central flow on colour Doppler **C** and **D** show a normal appendix in the same patient

Patients who presented with vomiting (74%) were more likely to get diagnosed with acute abdominal pain compared to those who were not vomiting (26%) of the 85 patients who presented with NTA 48 (56%) were managed medically and the remainder 37 (44%), were managed surgically. Of the surgically managed patients, the intra-op findings were in agreement with the sonographic findings in 97% of cases.

A proportion of 21% (18/85) were also imaged with plain radiography. For these patients, additional information was noted in 2 (11%) patients who had pneumoperitonium and had marked abdominal distension which made US difficult.

DISCUSSION

Ultrasound is an appropriate modality of investigating NTA in paediatric patients because of and its high sensitivity in finding some of the common conditions causing acute abdomen. This study therefore set out to describe sonographic findings in NTA abdominal emergencies in paediatrics at MNRH

The mode age group was 8-12 years which comprised 32 (37.6%) of all the patients. These findings were similar to other studies done elsewhere. A study done by Khalid *et al.*, also had majority of the patients, 50.7%, in the age group 9 to 12 years (Khalid, M. *et al.*, 2012).

Excluding abdominal pain, vomiting 59 patients (69%) and fever 56 (67%) were the most cited symptoms among the 85 patients with acute abdominal pain at MNRH. In a study done by Khalid *et al.*, showed that besides abdominal pain the commonest presentation were vomiting, constipation and fever (Khalid, M. *et al.*, 2012). The similarities in these two studies would be because the studies were done in areas with similar environmental factors. Khalid *et al.*, study was done in India which is a developing country just like Uganda so similar problems would be encountered in these areas; overpopulation, crowding poor nutrition and sanitation therefore majority of causes were of an infective nature.

In this study the three most frequent diagnoses were mesenteric lymphadenitis 18 (21.1%), ascites 14 (16.8%) and pneumoperitonium(10.6%) . Examples shown in figures 1-5 below. In a study done by Carter *et al.*, the three commonest causes of acute abdominal pain in childhood were, in young infants, intussusception, appendicitis and mesenteric adenitis (Carty, H. 2002). Similarly intussusception was a common cause of abdominal pain in infants in this study. However appendicitis was not as common as other studies and this may be because of the differences in diet (high fibre diet) as compared to the refined diet in Western countries (UK).

Ascites

Ultrasound scan in cases of peritonitis played a supportive role. Patients who had ascites with internal echoes and septations. The clinical features supported the diagnosis of peritonitis, raised white cell count generalised abdominal tenderness. Ascites was the second commonest ultrasound finding among patients with acute abdomen, 16.5% (14 patients). Twenty nine percent (Khalid, M. *et al.*, 2012) of the patients were surgically managed versus the 71% (10) who were medically managed. The common sonographic findings in patients who were taken to theatre was a deeper pool (>5cm) of free peritoneal fluid and more echogenic foci within these pools as compared to the shallower pools (<2cm) and less echogenic debris in those medically managed, examples in figure 2.

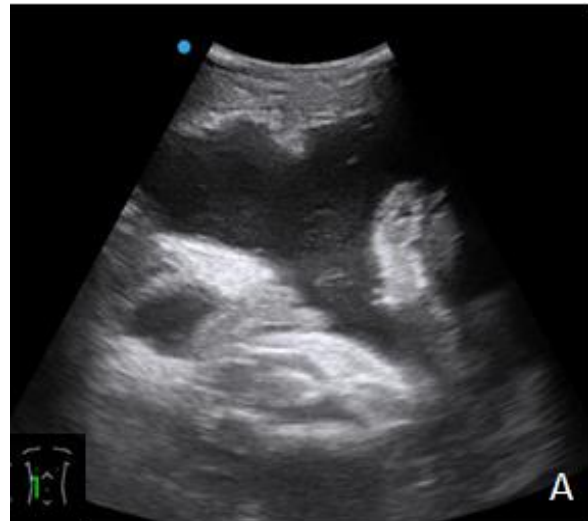

Figure 2. US images in a 11 year old female patient who presented with 4 day history of abdominal pain and distension. US show free peritoneal fluid of 7cm depth with internal echoes.

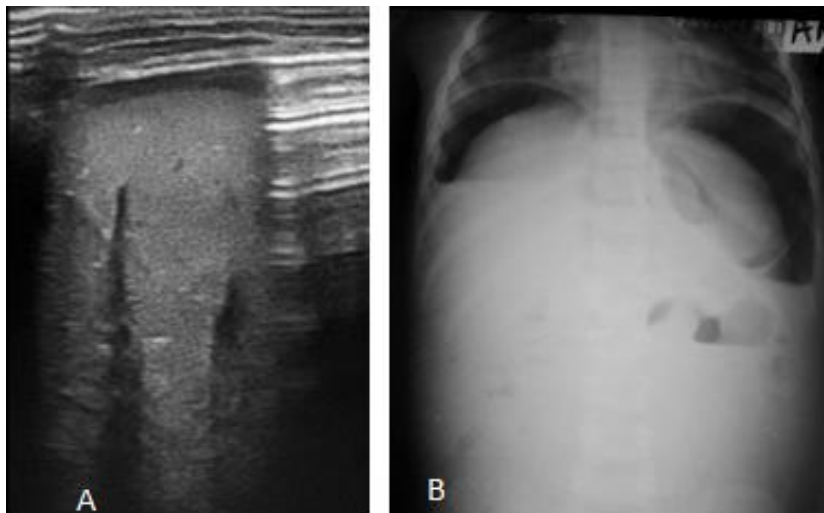


Figure3. A Longitudinal US image in a 7 month old patient who presented with a 4 day history of generalised abdominal pain, constipation and fever show linear area of increased echogenicity with distal ring-down reverberation artefact indicative of free peritoneal air. B Erect abdominal X-ray show air under the diaphragms.

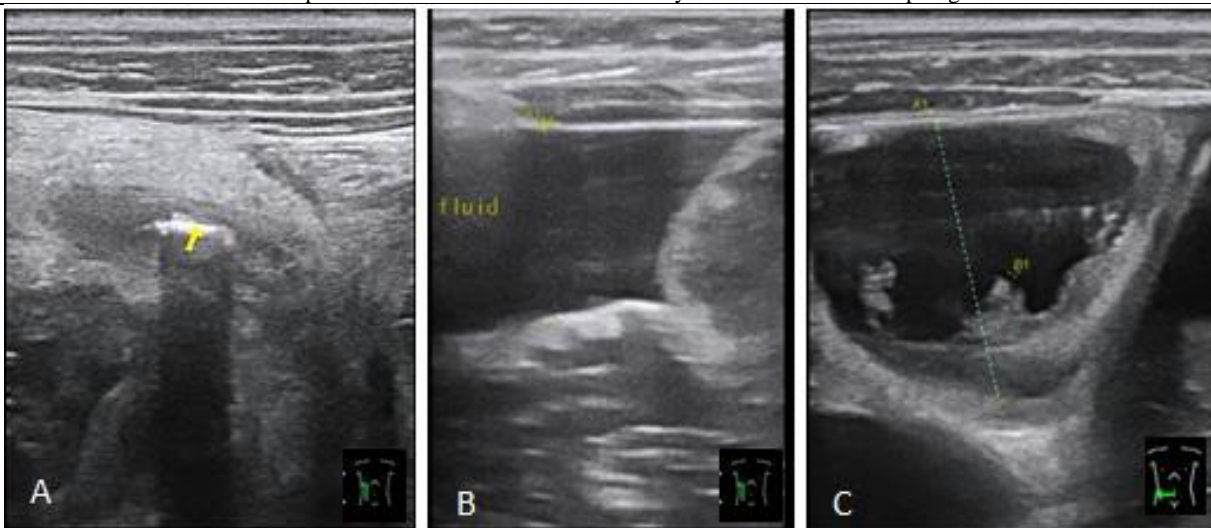


Figure4. Ultrasound image of a 10 year old. A show an appendix with imperceptible walls and an echogenic linear structure within (appendicolith). B Longitudinal US in the RIF show free peritoneal fluid with echoes. C transverse US in the RIF show dilated loops of bowel with no peristalsis.

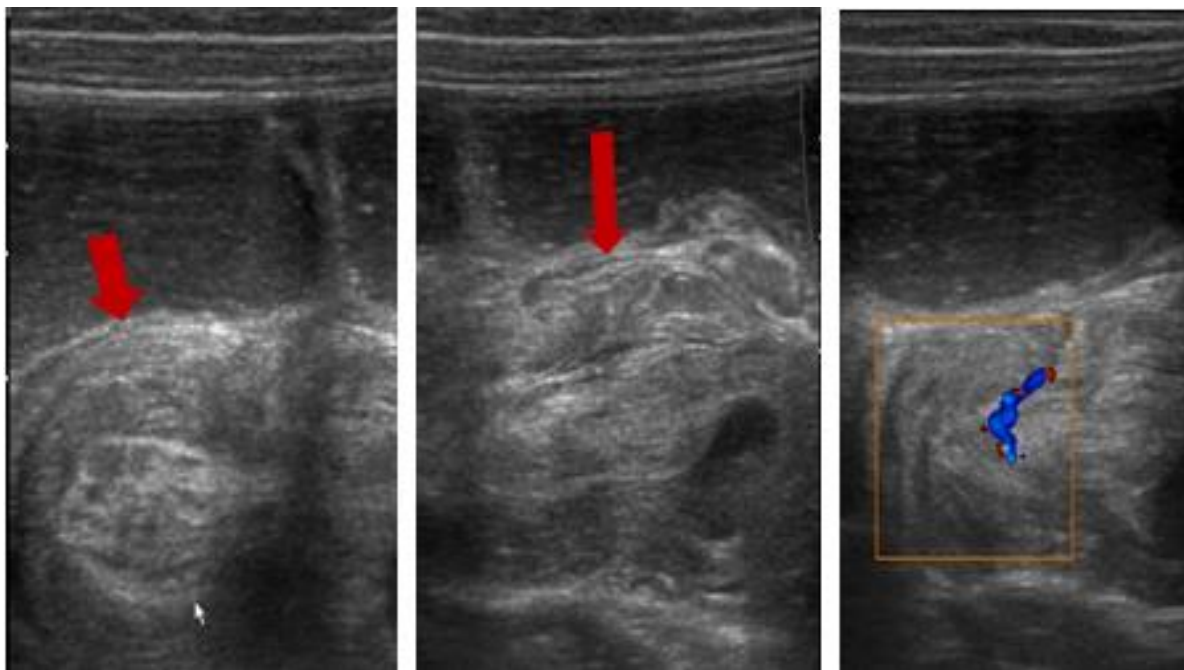


Figure 5. A-C Transverse, Longitudinal and Colour Doppler U/S images in a 4 month old with intussusception presented with 4/7 day history of abdominal distension, passing blood stained stool shows a doughnut sign, hayfork sign in longitudinal and central blood flow.

Patients who presented with vomiting (74%) were more likely to get diagnosed with acute abdominal pain compared to those who were not vomiting (26%). The association between vomiting and radiological findings is probably because most of the conditions involved the GIT system. The control and induction of vomiting is regulated in the medulla and it responds to signals from all over the body including the GIT (Wolfson, A. B. *et al.*, 2012).

The majority of patients, 56%, were managed medically while 44% were managed surgically. Of the 37 patients who were surgically managed, 95% were in agreement with sonographic findings. In a study done by Khalid *et al.*, 24.7% of patients were surgically managed whilst 4.1% had therapeutic interventions and the majority of the patients, 71%, were medically managed (Khalid, M. *et al.*, 2012). These findings were similar probably because of the similar environments in which both studies were done.

In conclusion the commonest causes of NTA in paediatric patients at MNRH were peritonitis, mesenteric lymphadenitis and pneumoperitonium. The most common US diagnosis in infants was intussusception 6 (29%), while children 1-3 years were mostly diagnosed with mesenteric lymphadenitis 3(27%) and ascites 3(27%), those aged between 4-7 years 6 (40%); 8-12 years 7 (25%) were mostly diagnosed with mesenteric lymphadenitis.

REFERENCES

1. Babcock, D. S. (2002). Sonography of the acute abdomen in the pediatric patient. *Journal of ultrasound in medicine*, 21(8), 887-899.
2. Balachandran, B., Singhi, S., & Lal, S. (2013). Emergency management of acute abdomen in children. *The Indian Journal of Pediatrics*, 80(3), 226-234.
3. Carty, H. (2002). Paediatric emergencies: non-traumatic abdominal emergencies. *European radiology*, 12(12), 2835-2848.
4. Khalid, M., Redhu, N., Nazir, B., Khalid, S., Chana, R. S., & Jha, A. (2012). Diagnostic value of ultrasonography in evaluation and management of acute abdominal conditions in the paediatric age group. *African Journal of Paediatric Surgery*, 9(3), 198.
5. Mazzei, M. A., Guerrini, S., Squitieri, N. C., Cagini, L., Macarini, L., Coppolino, F., ... & Volterrani, L. (2013). The role of US examination in the management of acute abdomen. *Critical ultrasound journal*, 5(S1), S6.
6. Scholer, S. J., Pituch, K., Orr, D. P., & Dittus, R. S. (1996). Clinical outcomes of children with acute abdominal pain. *Pediatrics*, 98(4), 680-685.
7. Wolfson, A. B., Hendey, G. W., Ling, L. J., Rosen, C. L., Schaider, J. J., & Sharieff, G. Q. (2012). *Harwood-Nuss' clinical practice of emergency medicine*. Lippincott Williams & Wilkins.